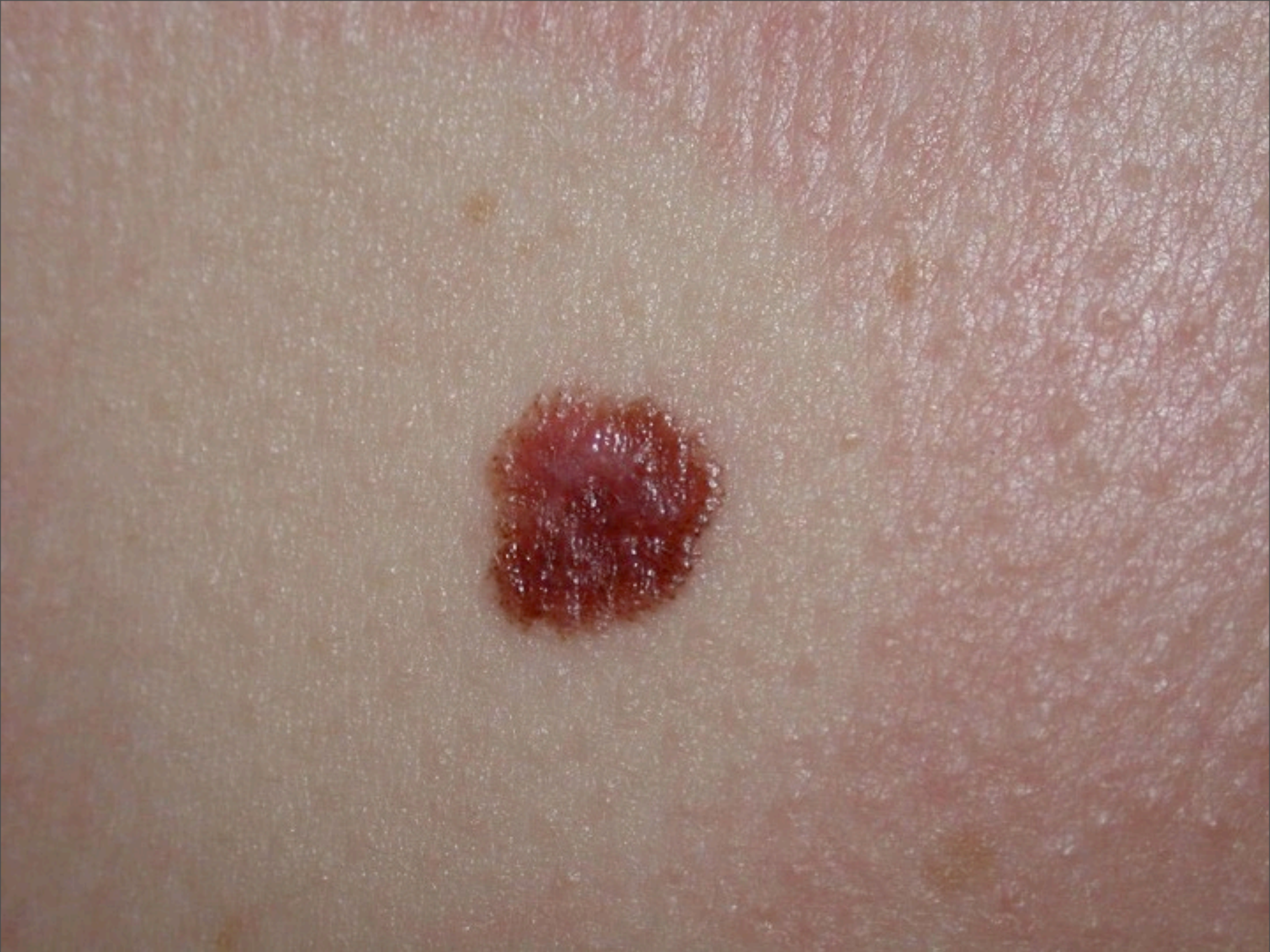

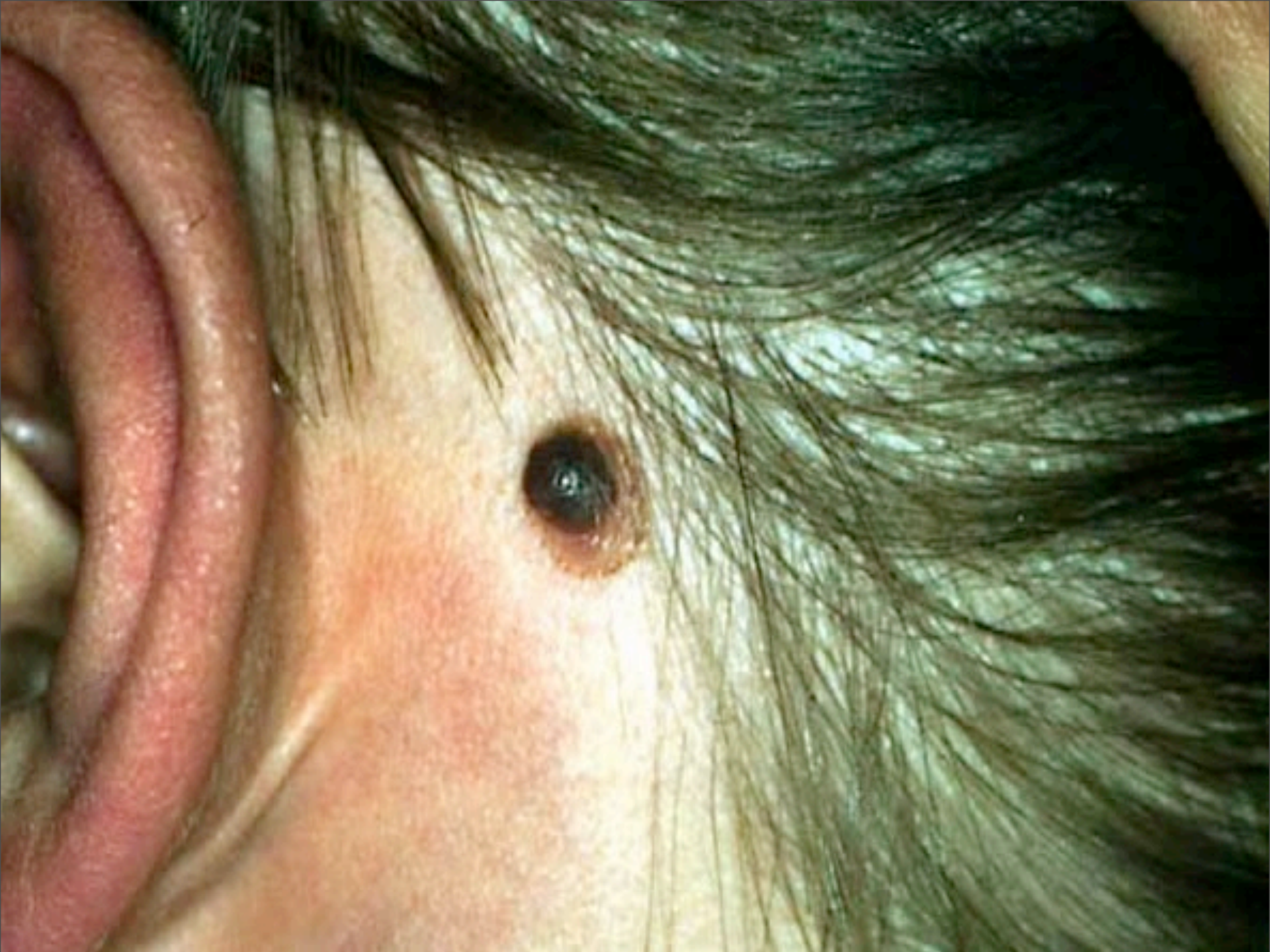# Spitz Nevus

Paul K. Shitabata, M.D.  
Dermatopathology Institute



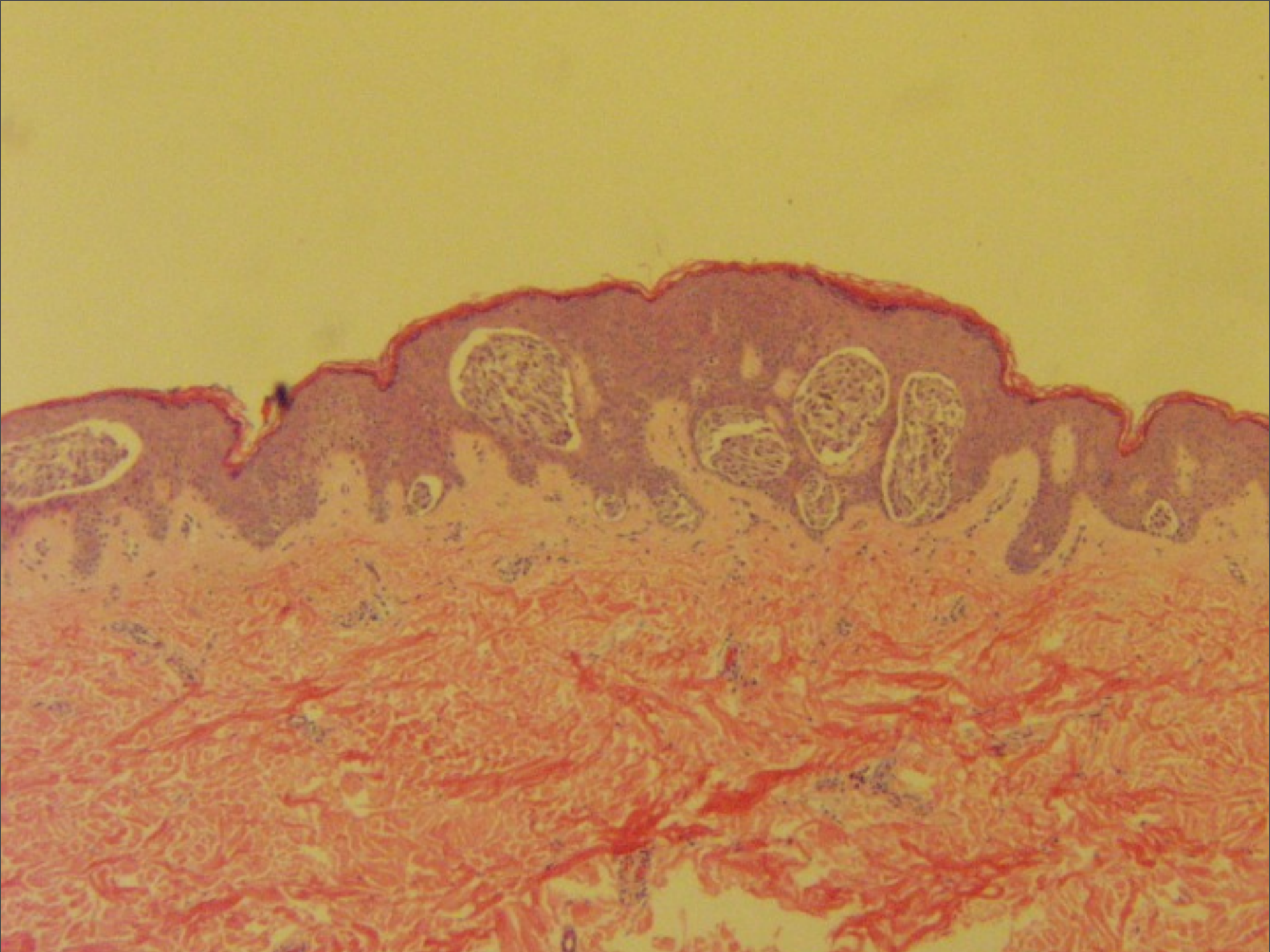
Thursday, May 23, 13



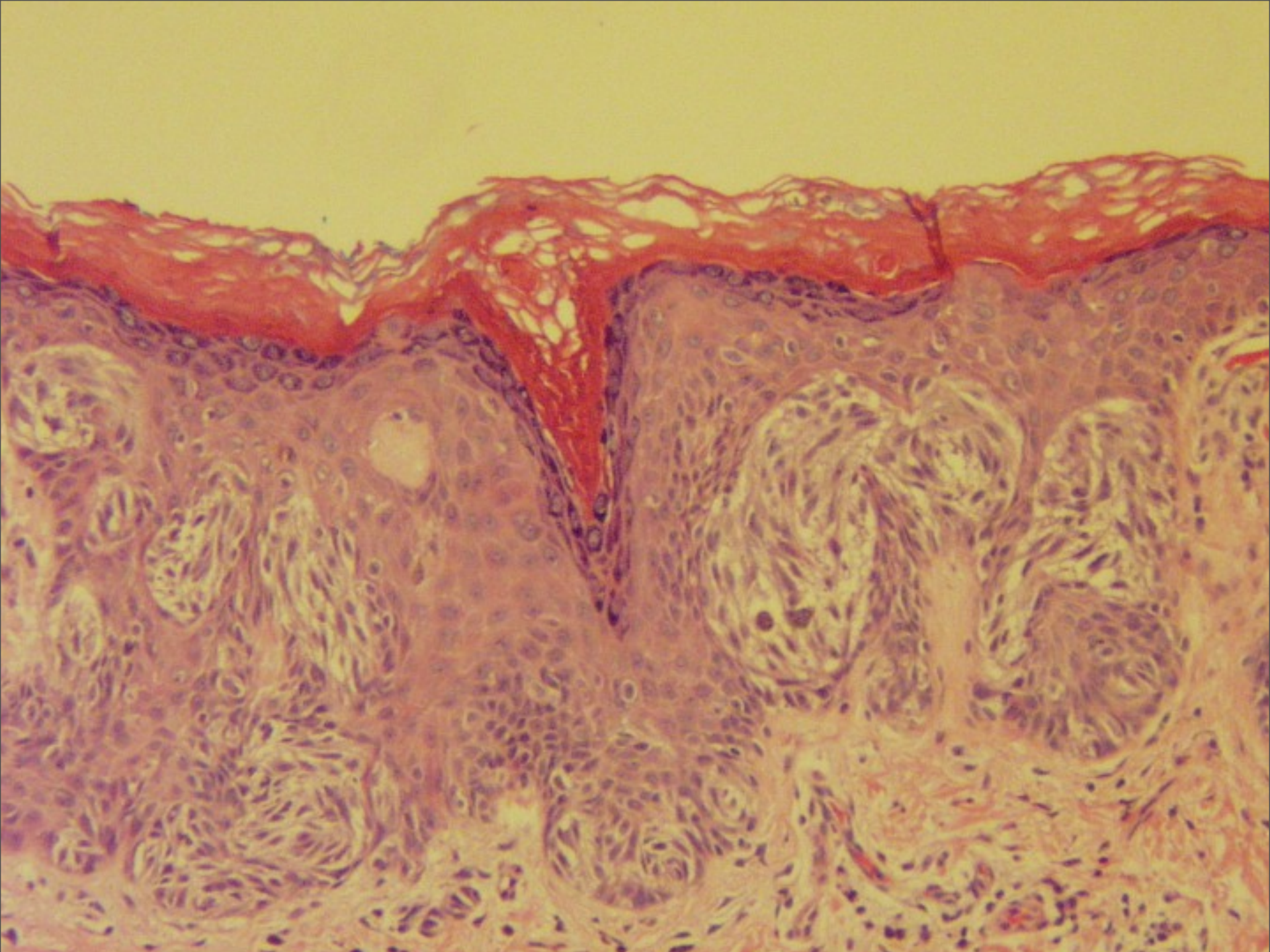


Thursday, May 23, 13

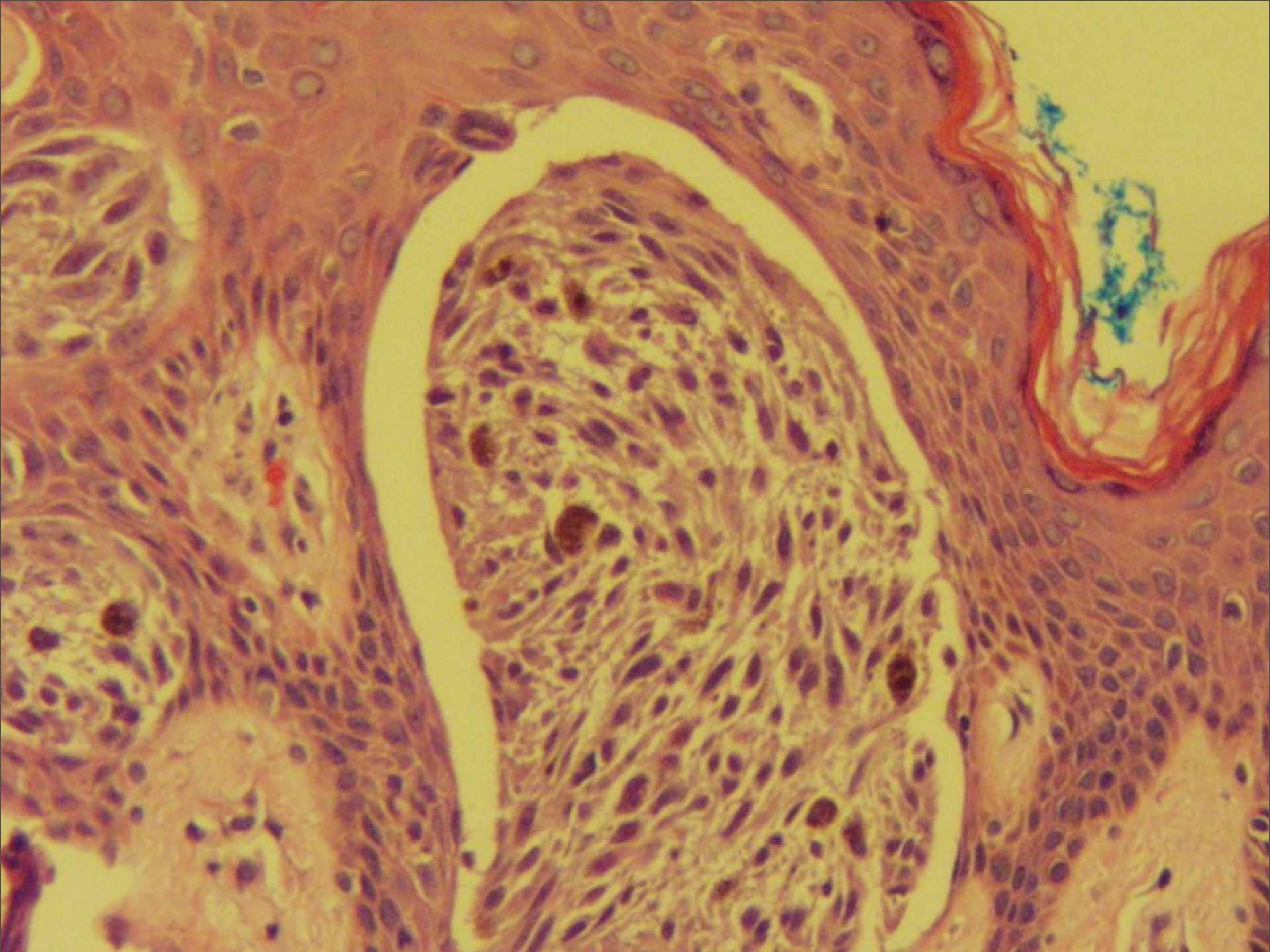




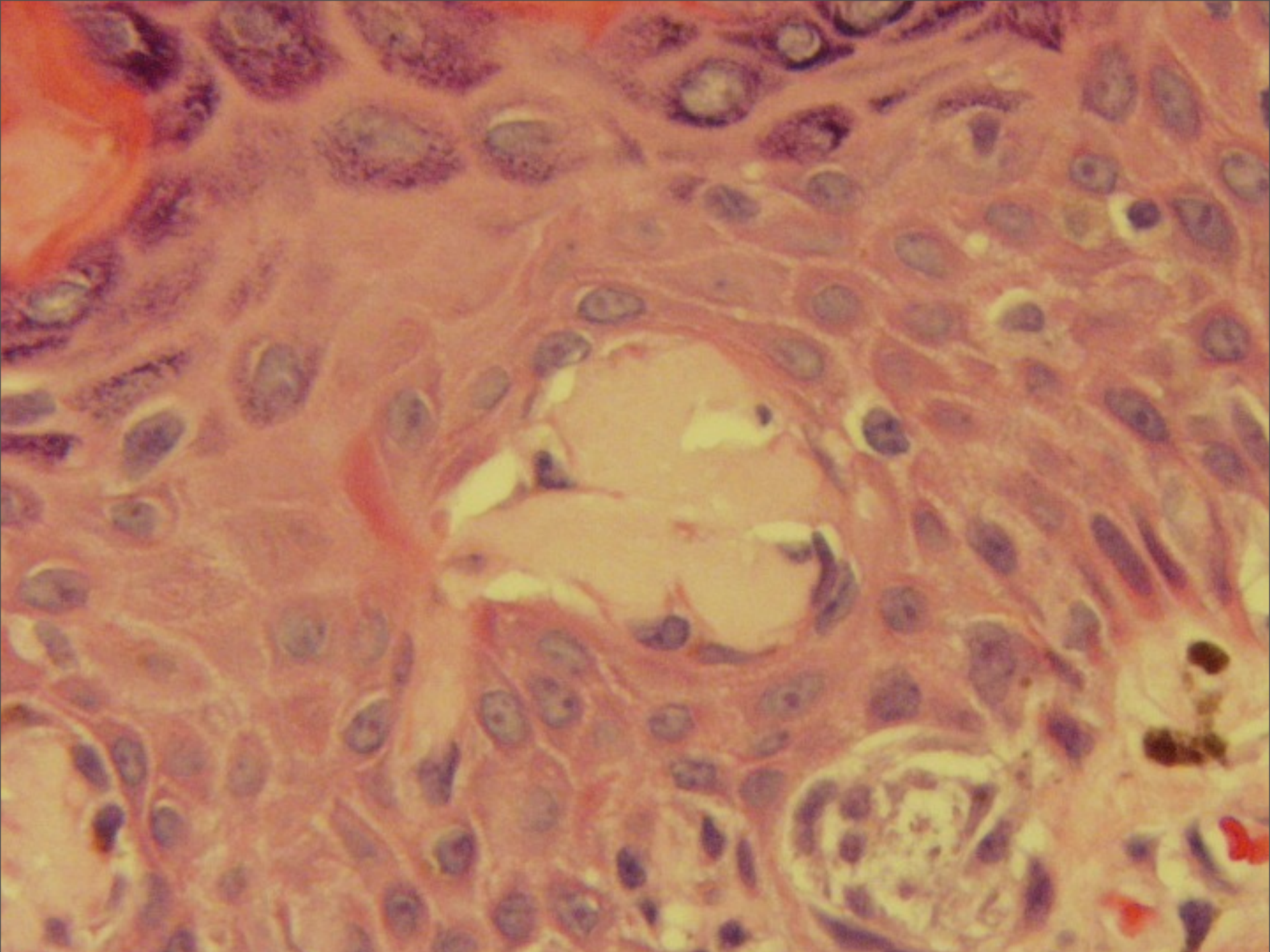




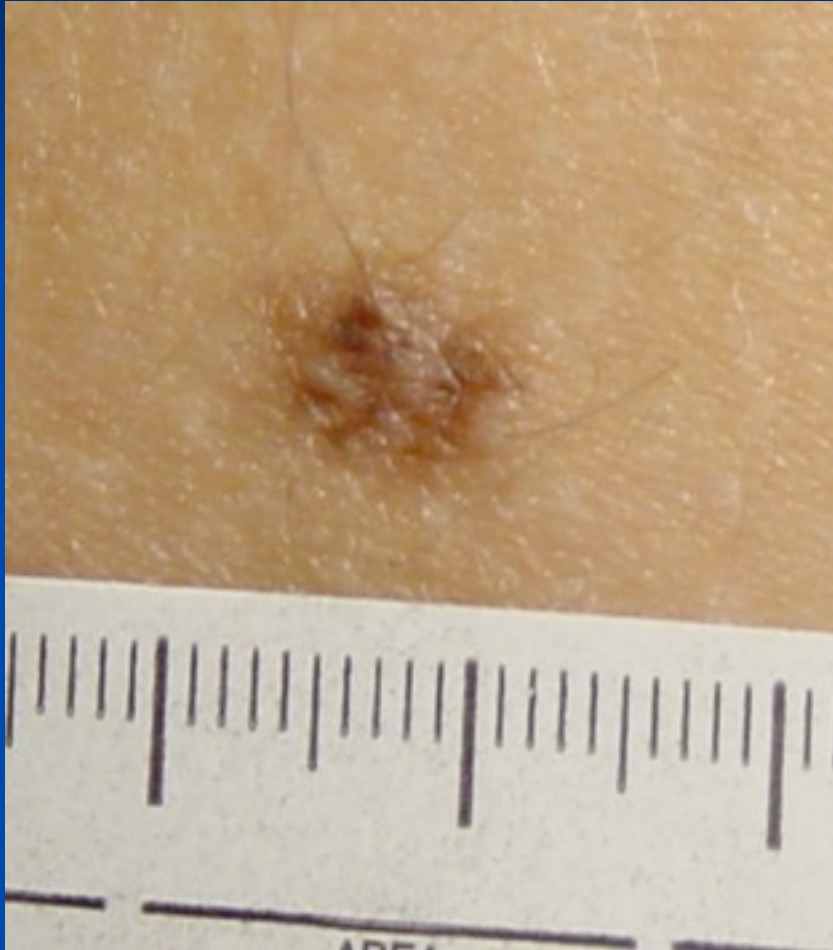








# Sophie Spitz (1948) Juvenile Melanoma



- Childhood lesions that histologically resembled malignant melanoma
- Behaved as benign tumors
- 12 of 13 patients initially diagnosed as having melanoma alive 13 years later
- Depth of invasion of these lesions did not correlate with prognosis



# Terminologic Confusion

Benign juvenile melanoma

Epithelioid or spindle cell nevocmelanocytic nevus

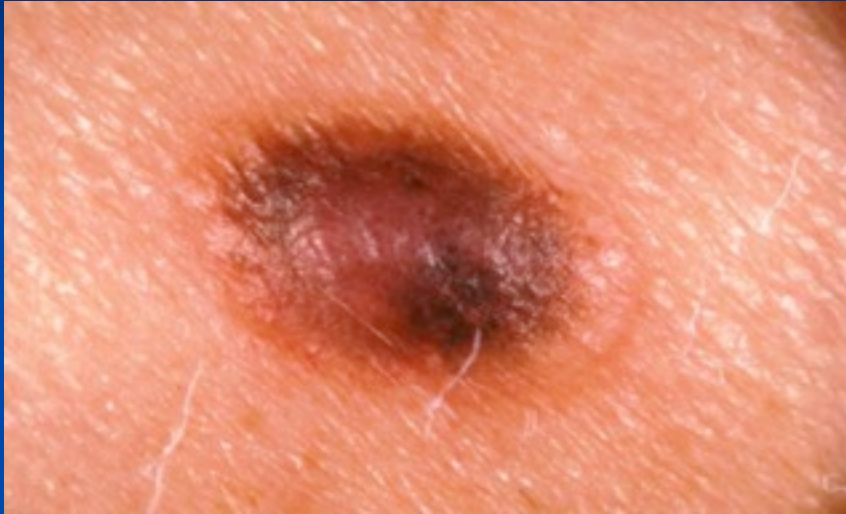Spitz tumor

Pseudomelanoma

Spindle cell nevus

Epithelioid cell nevus

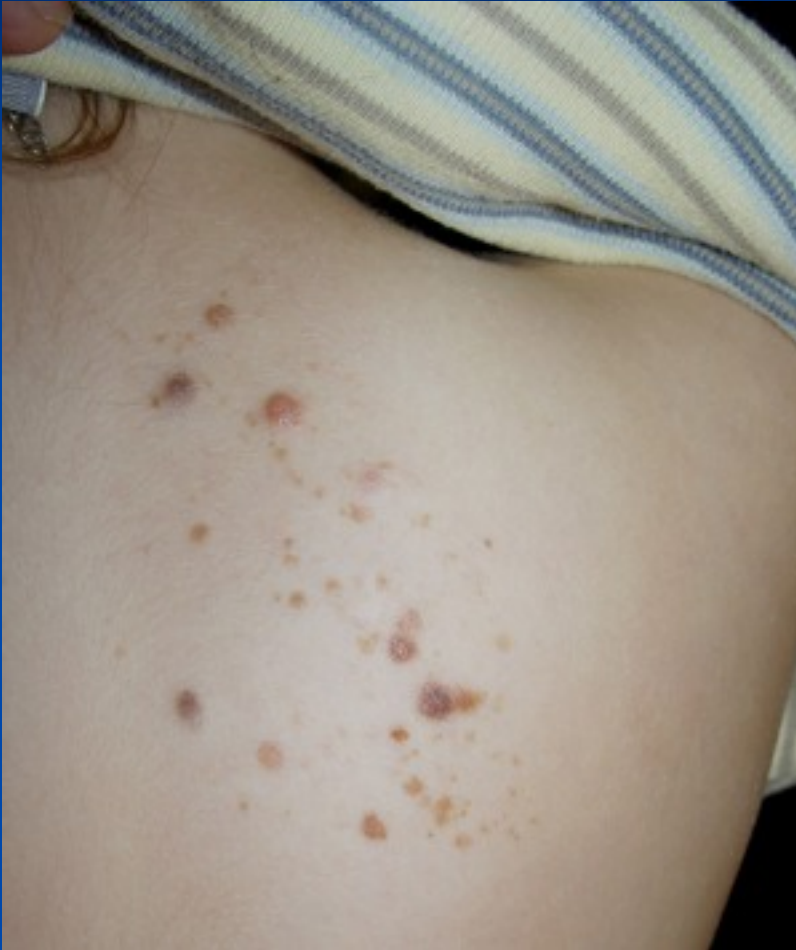# How Common?



- Incidence 1-10%
- First two decades of life
- Caucasians
- Head and neck
- Legs in women



# Four Clinical Variants

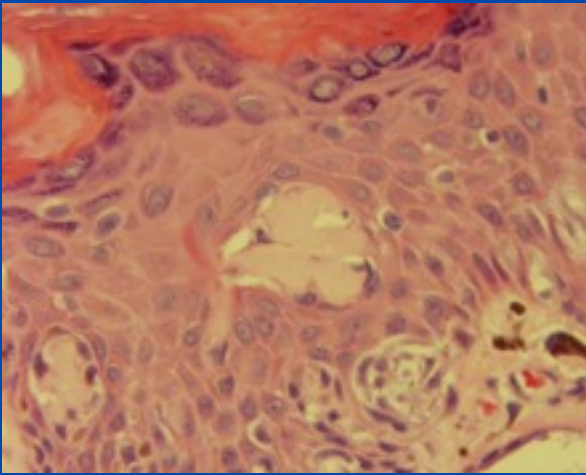


- Light-colored and soft lesions, which are usually smooth and pink or slightly pigmented
- Light-colored and hard lesions, resembling a dermatofibroma or a keloid
- Dark-colored lesions with varying degrees of pigmentation
- Multiple or agminated lesions

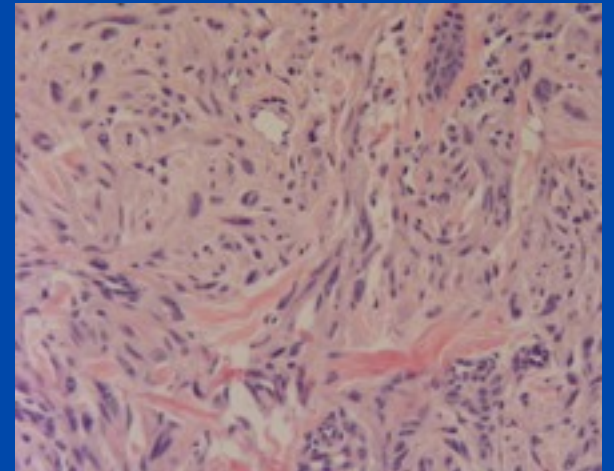
## Clinical criteria of Spitz nevus and malignant melanoma

Criterion	Spitz nevus	Malignant melanoma
Symmetry	Yes	No, except for early lesions and the rare nodular form of melanoma
Diameter <6 mm	Often	No in most cases; early lesions may be small
Ulceration and pruritus	Rare	Common
Age predominance	Children and young adults	Generally adults
Evidence of regression	No	Present in 23%
Recurrence after incomplete excision	4% to 5%	Likely
Metastatic potential	None	High

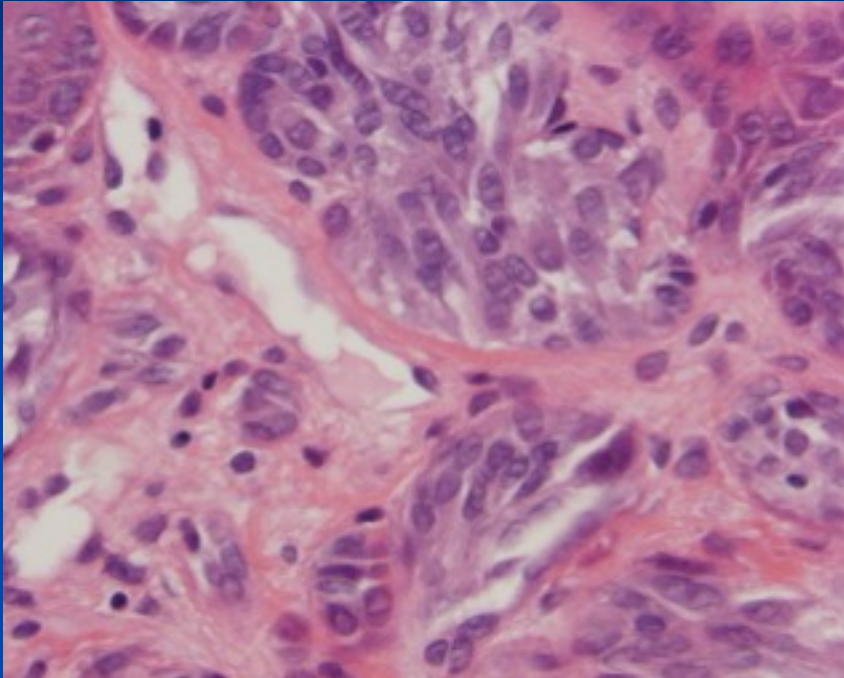




# Histopathology

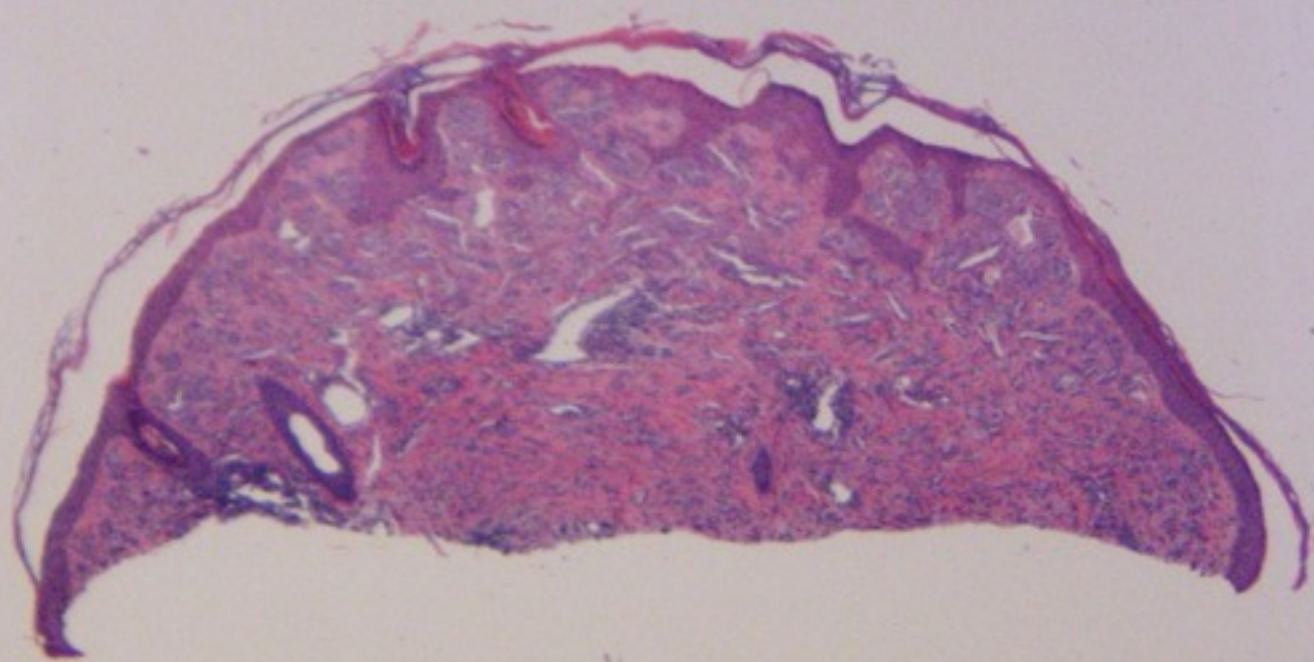


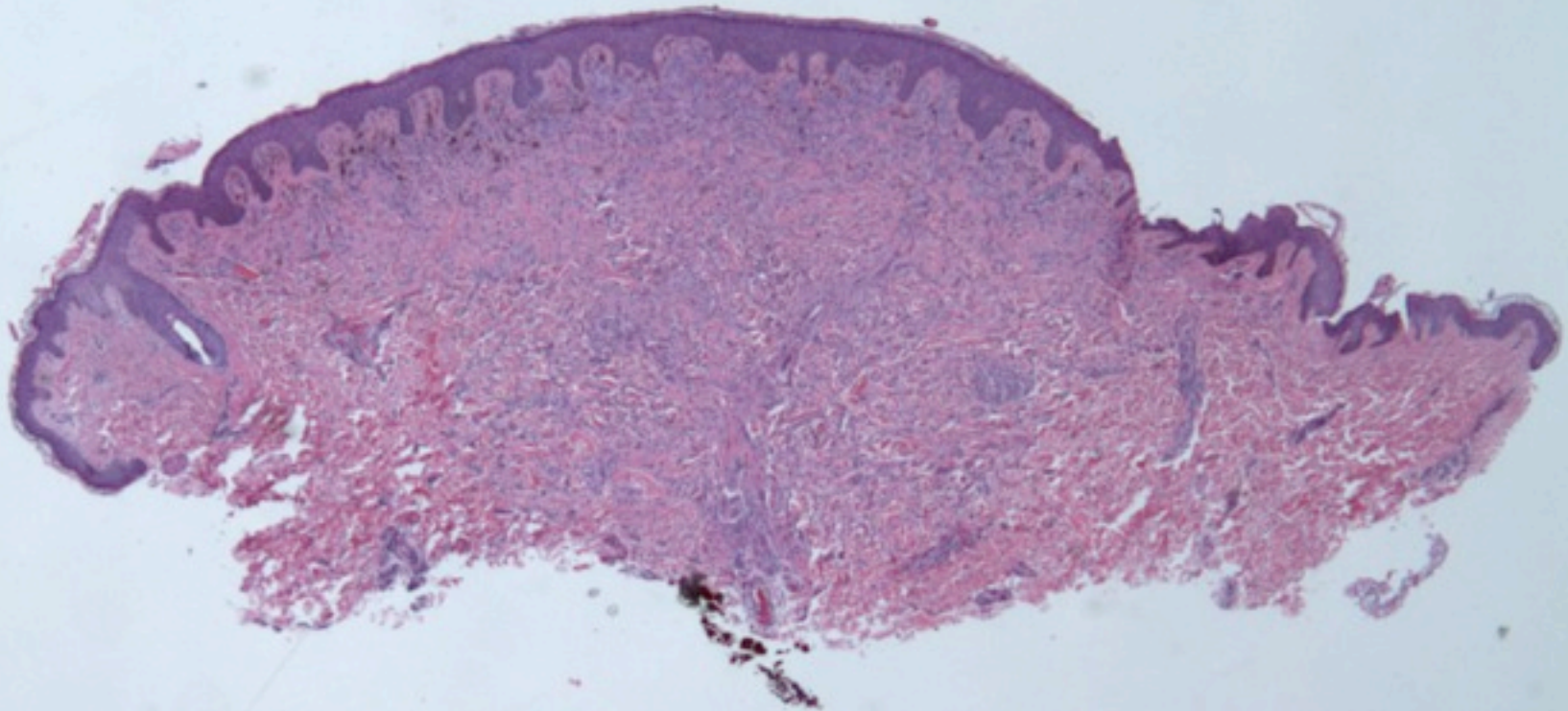
# Criteria



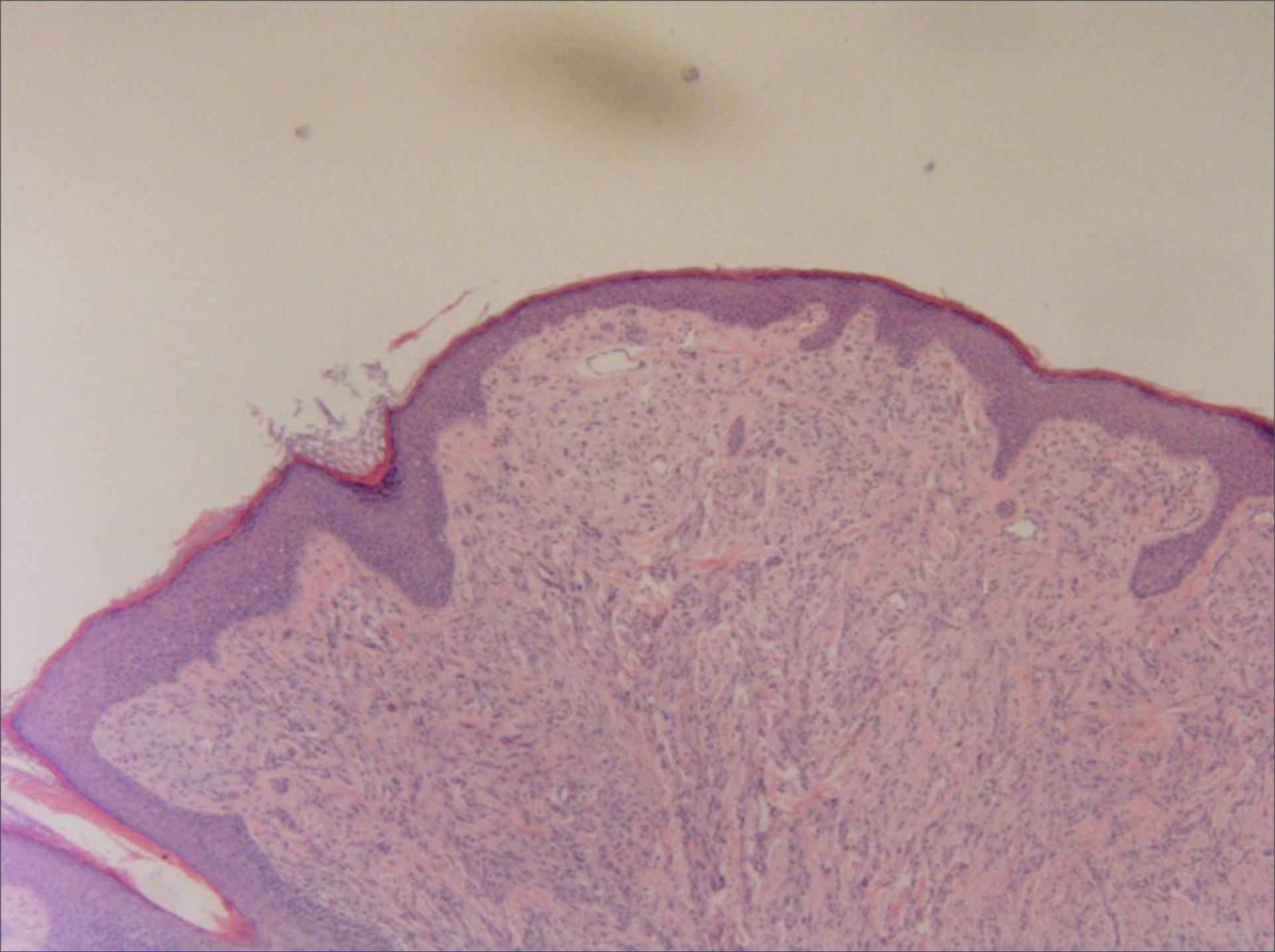
- Symmetry
- Borders
- Cell type
- Maturation
- Absent pagetoid spread of single cells.
- Kamino bodies

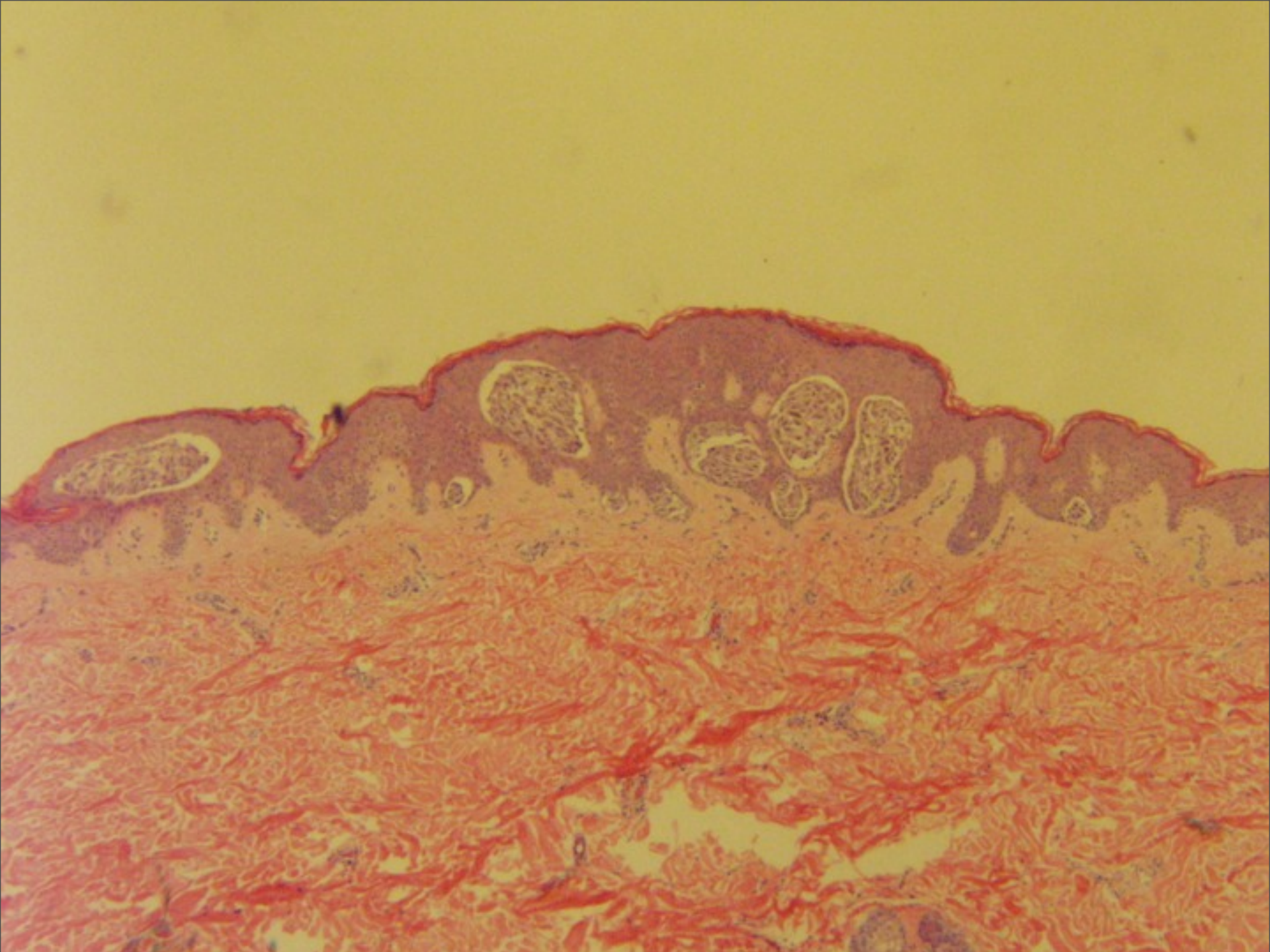






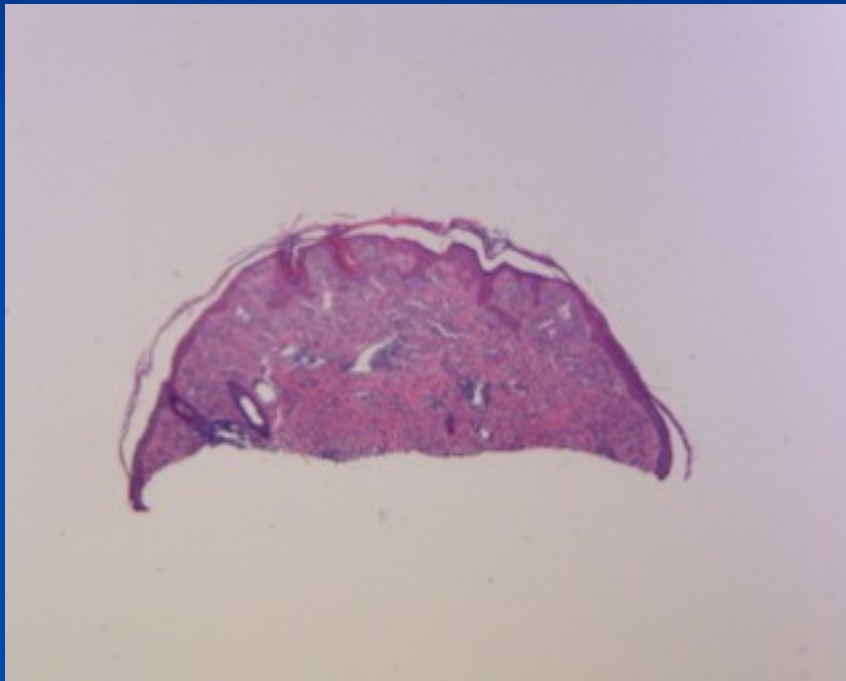




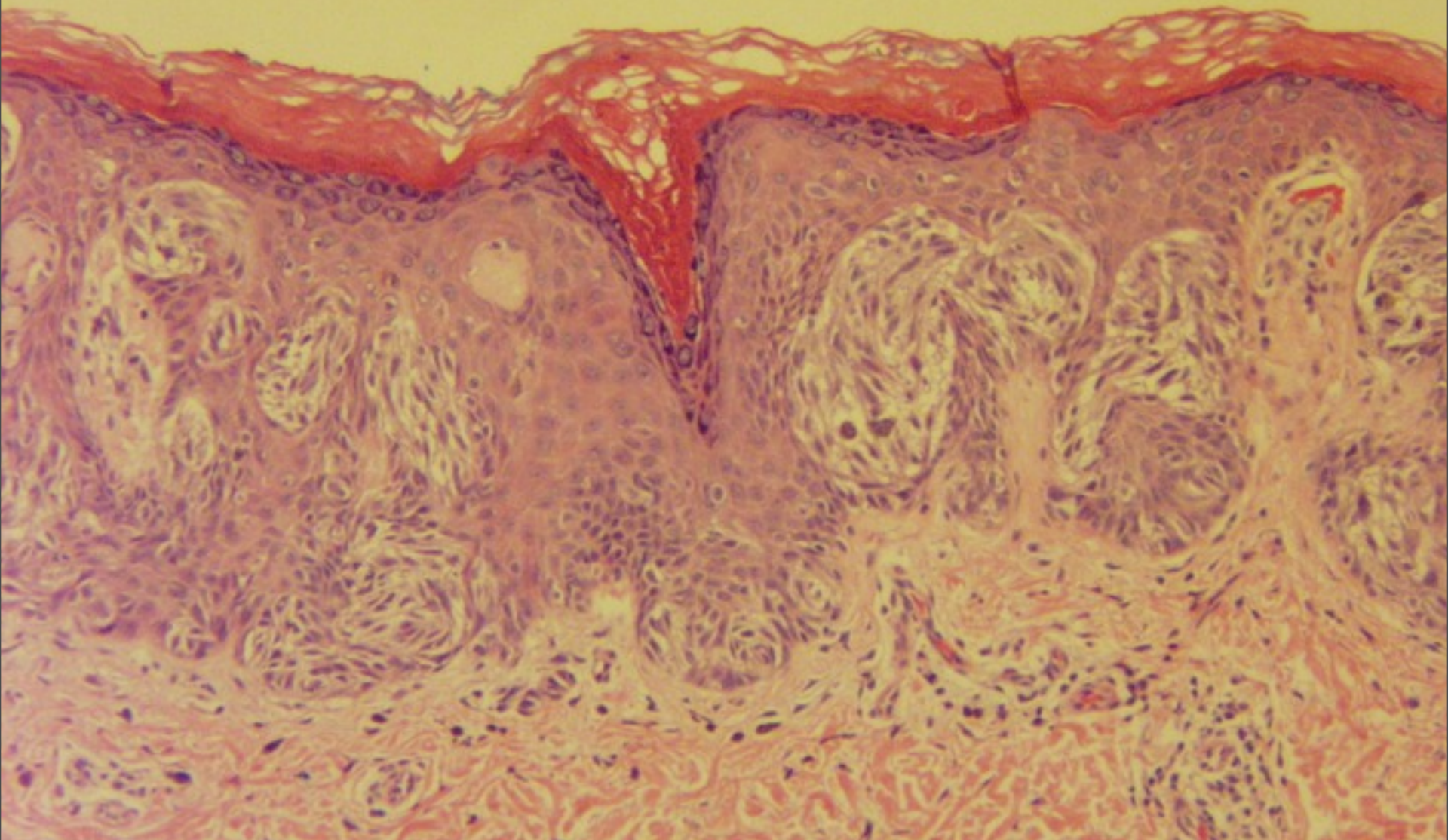




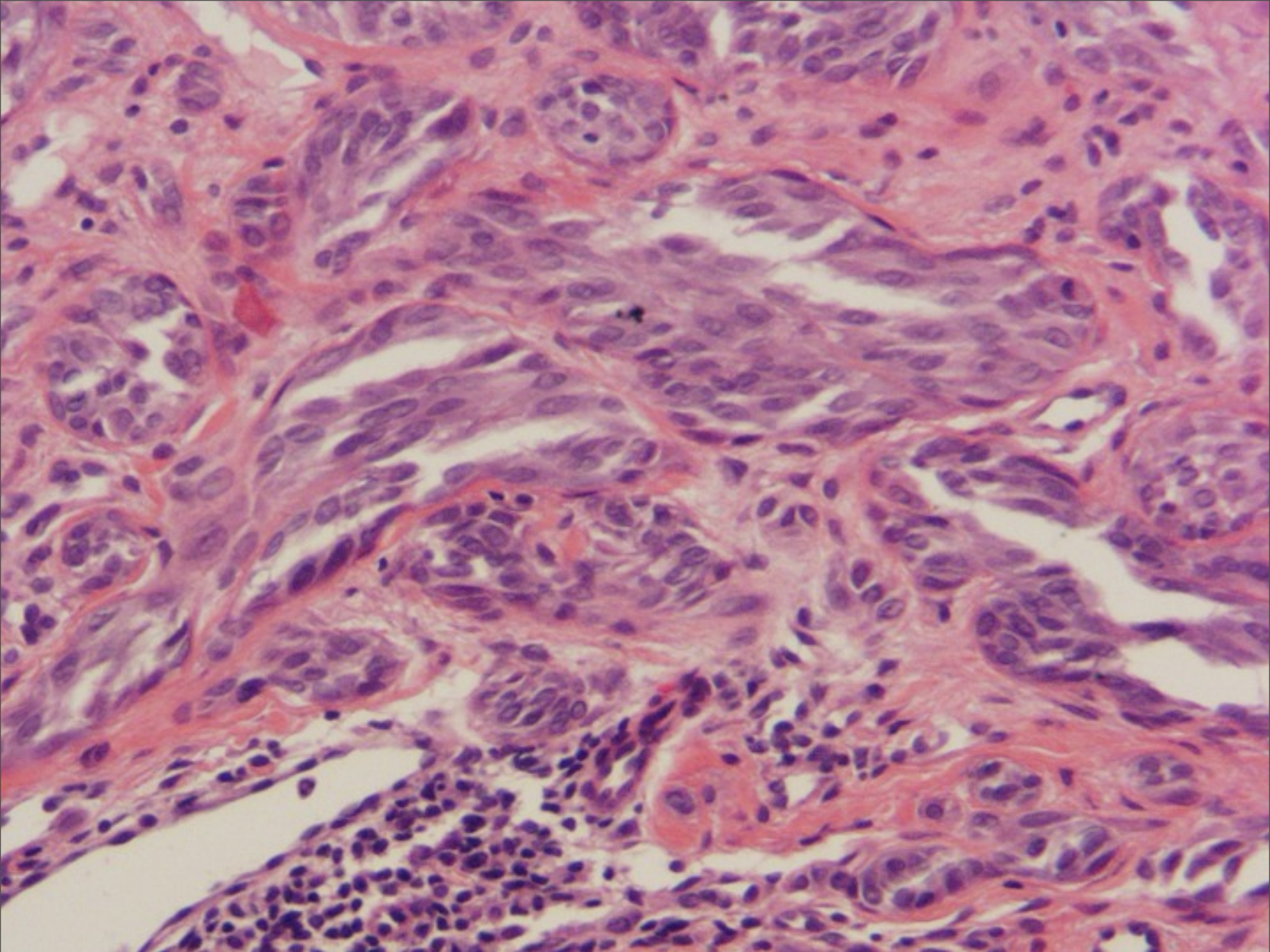
# Symmetry



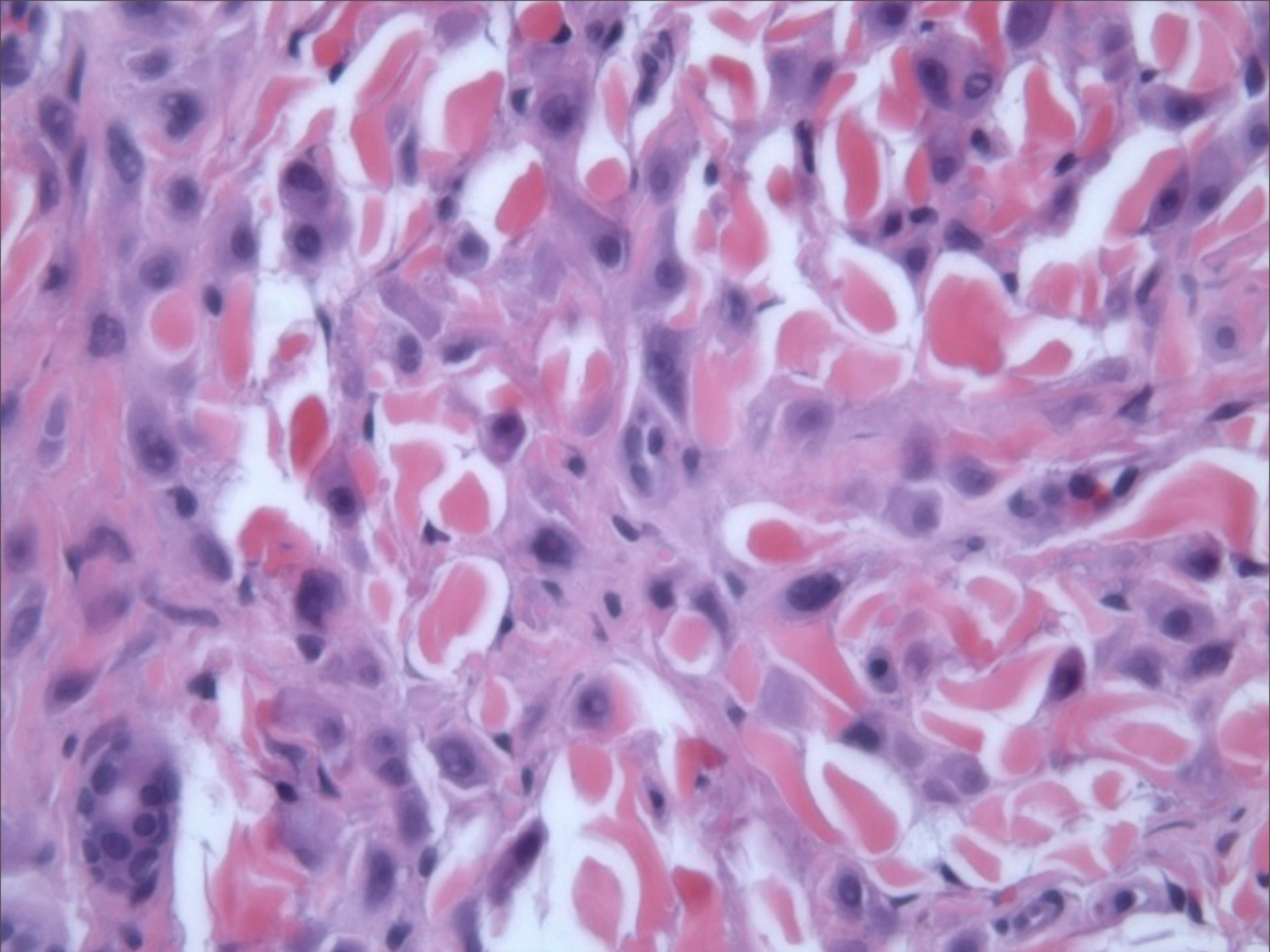
- No lateral extension of junctional activity beyond the limits of dermal component
- Similarity comparing one field with another
- Peripheral borders sharply circumscribed





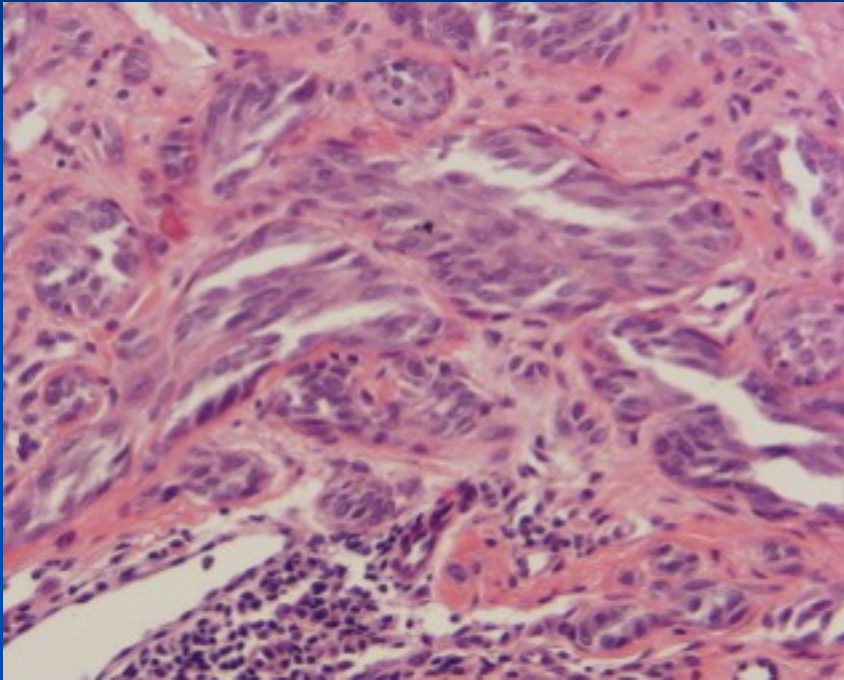




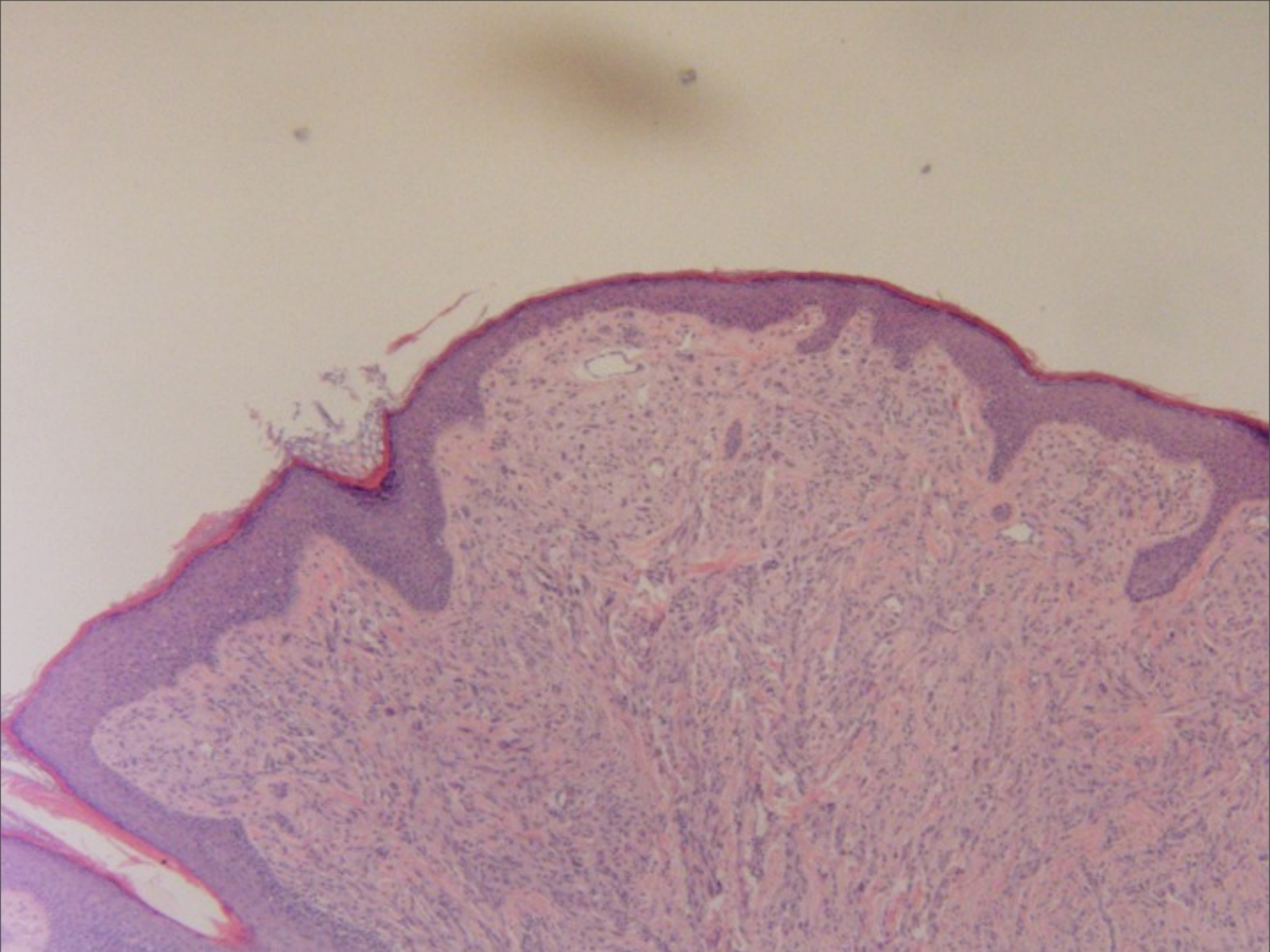




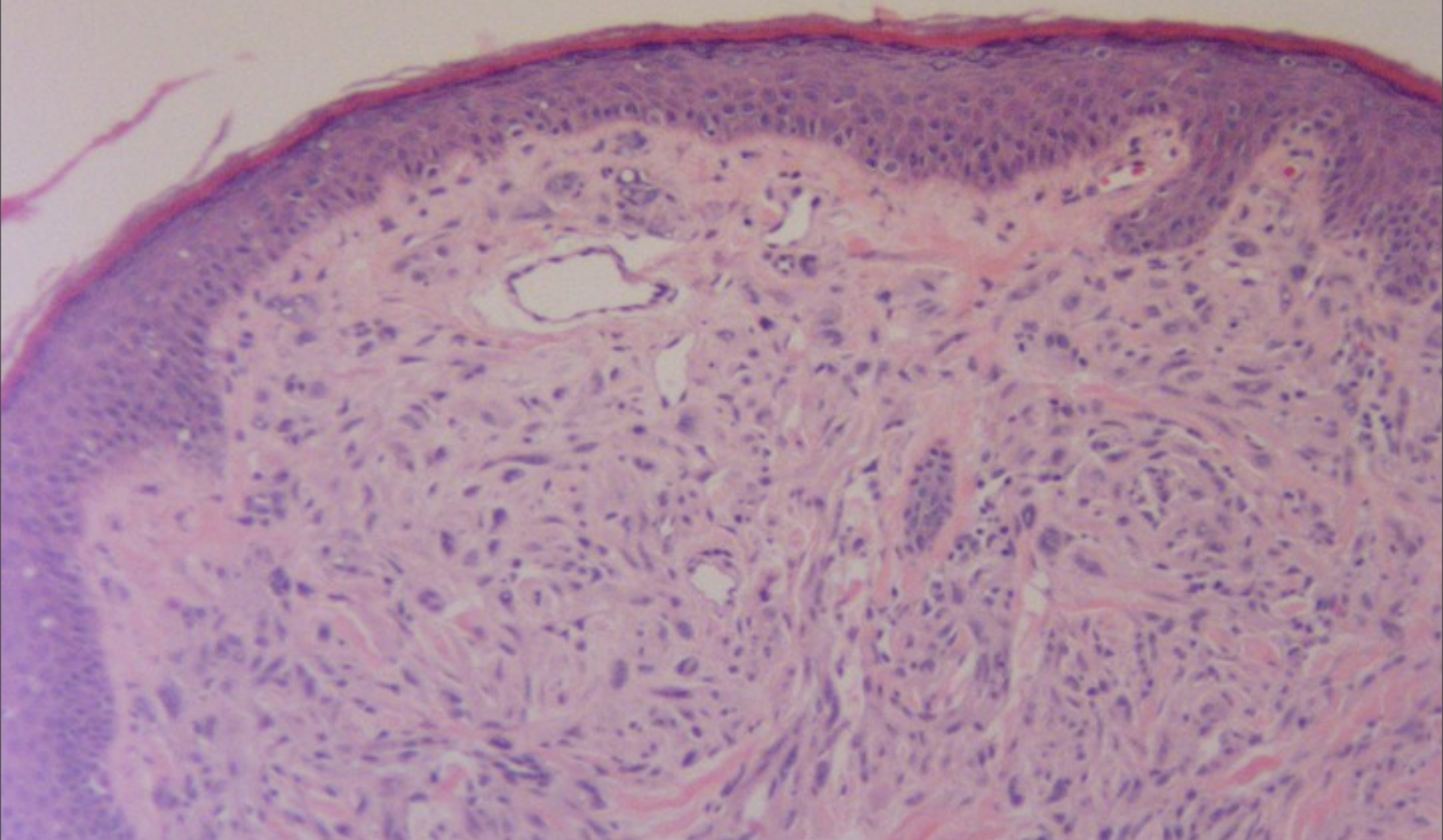
# Epithelioid and Spindle Cells



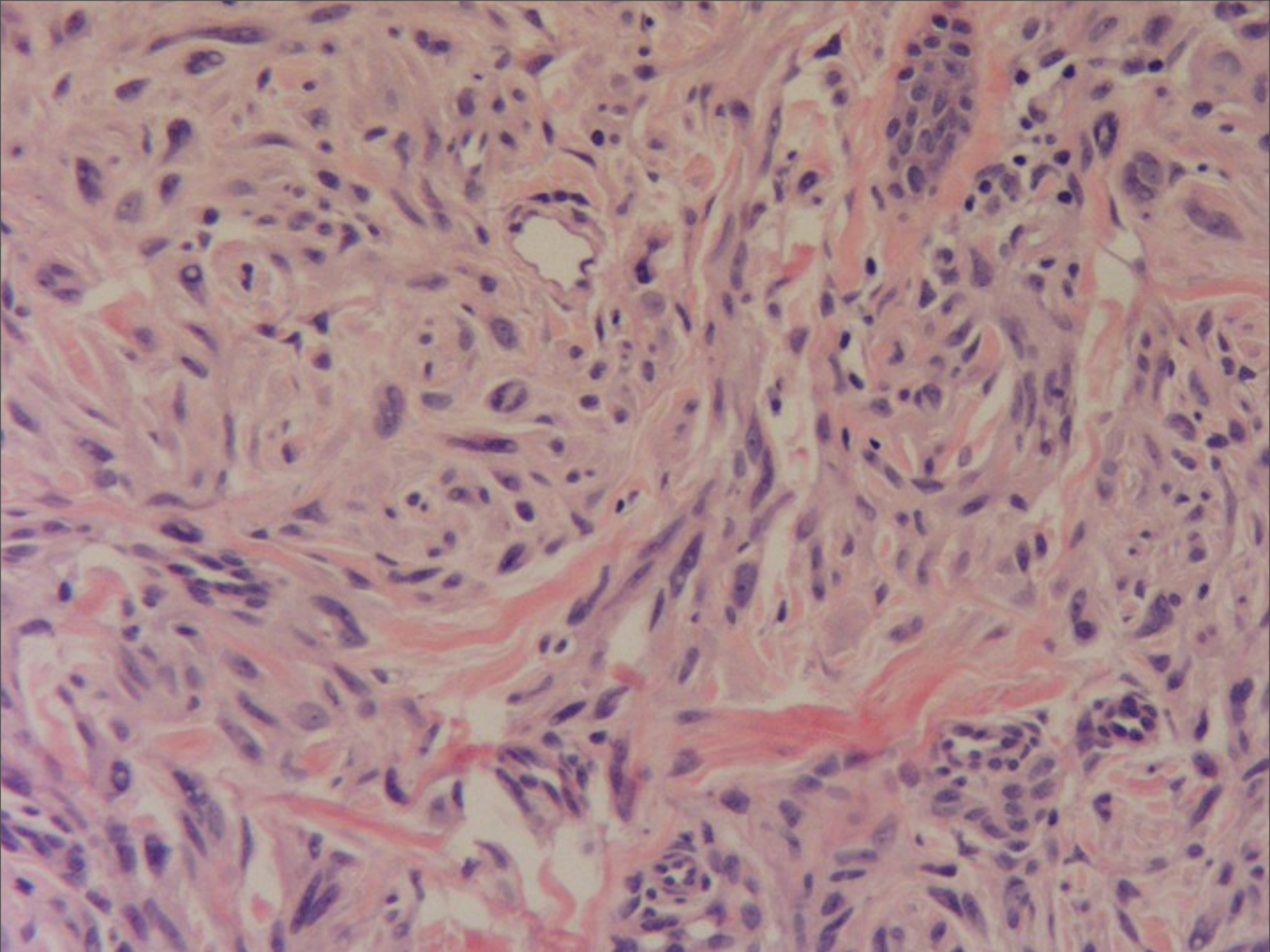
- Spindle cells more common
- Cells are arranged in fascicles with vertical orientation related to the rete ridges-”raining, streaming fish”
- Beware junctional epithelioid melanocytes in adult



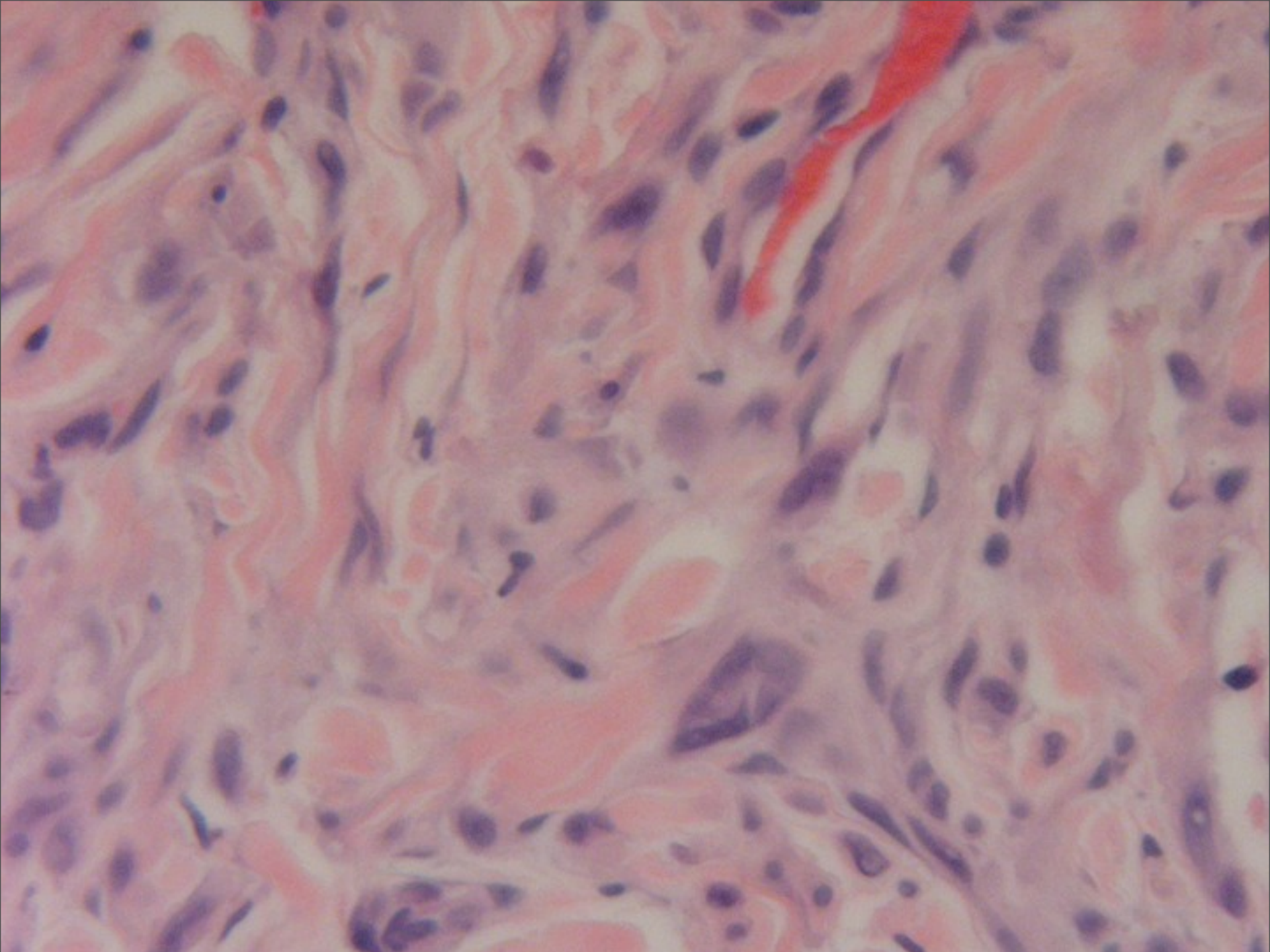




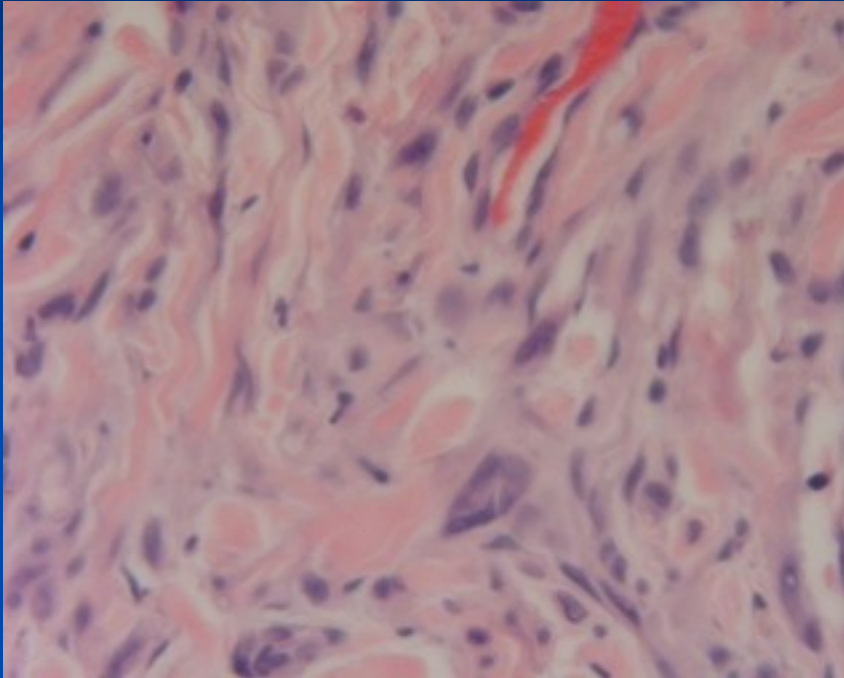






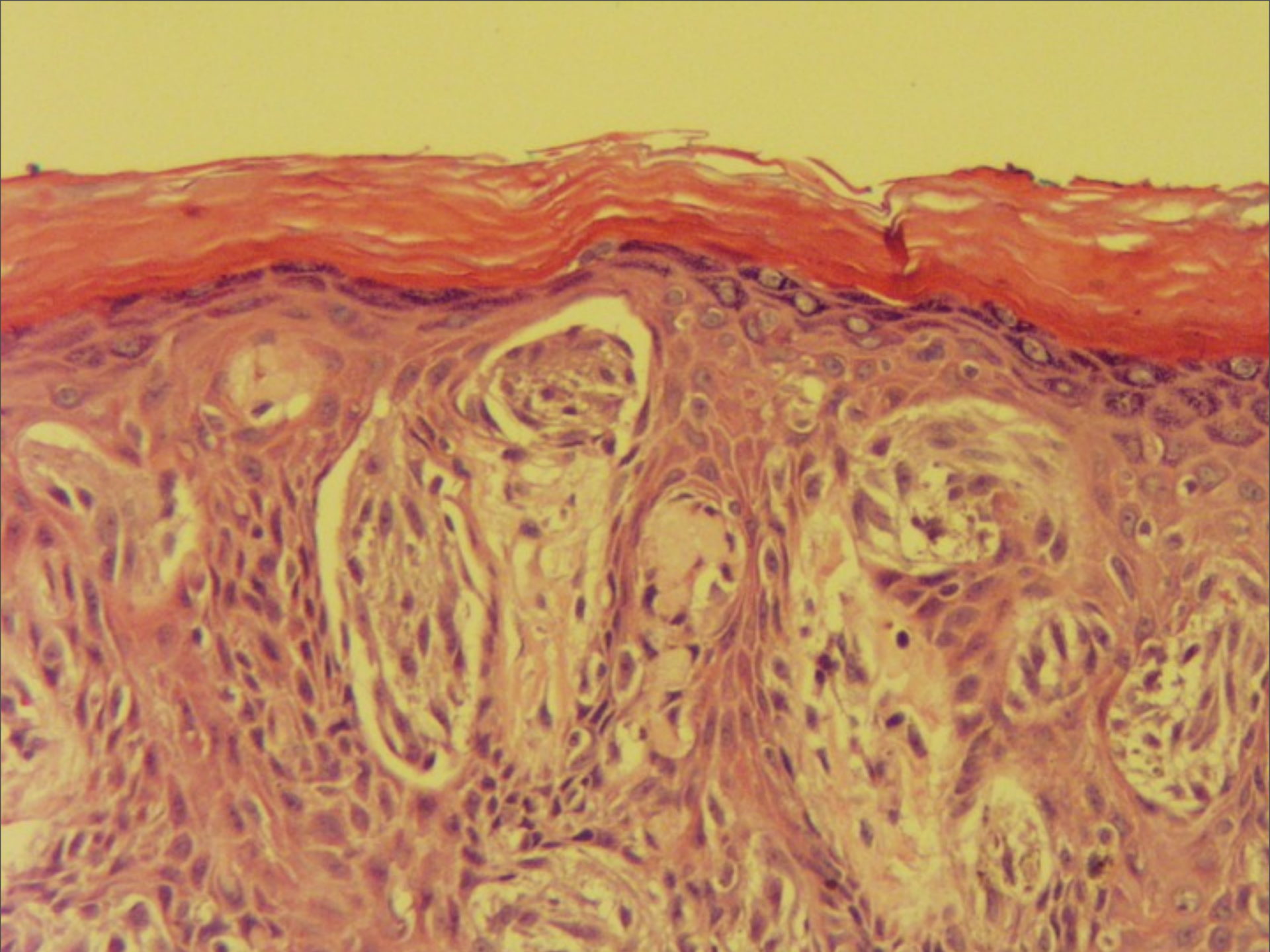


# Maturation

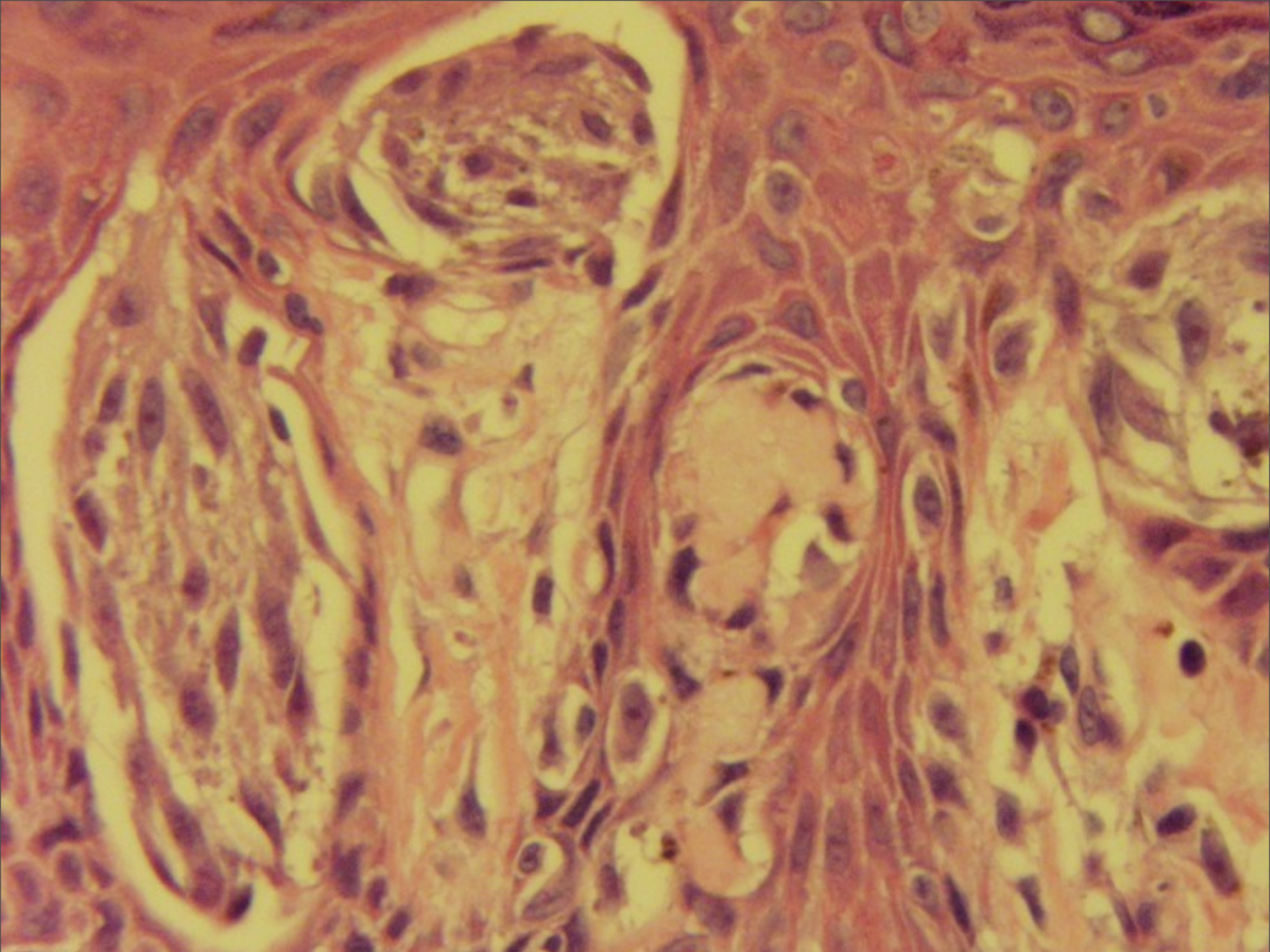


- Presence of small , normal nevus cells in the deeper part of the lesion
- No prominent nests at base
- Diminution of size of both nuclei and nucleoli

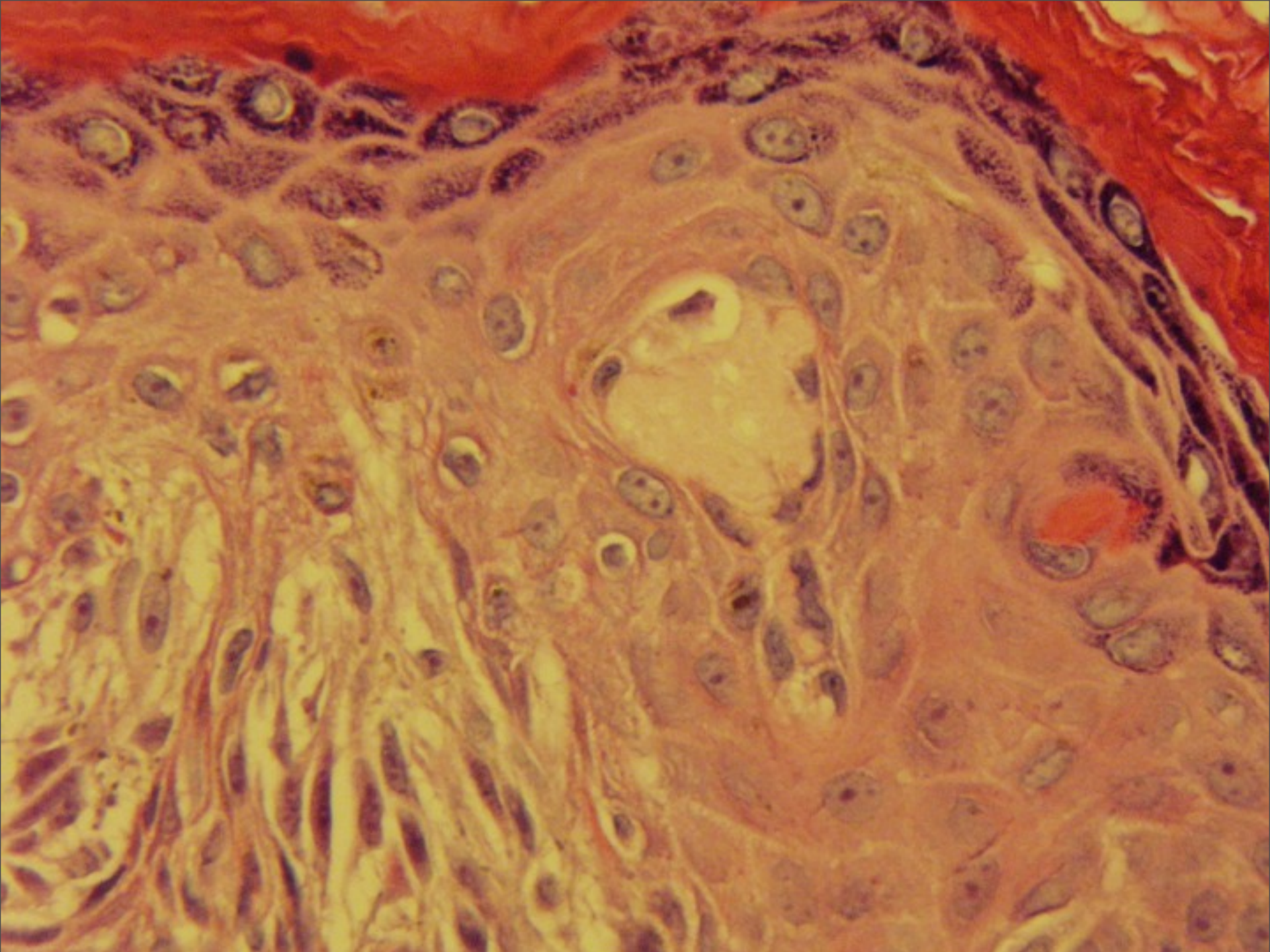




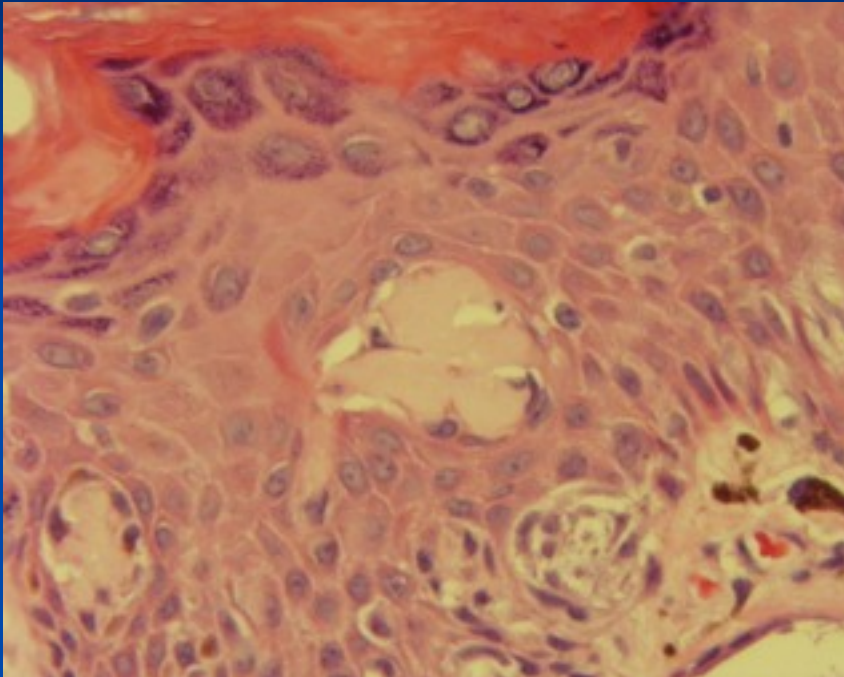








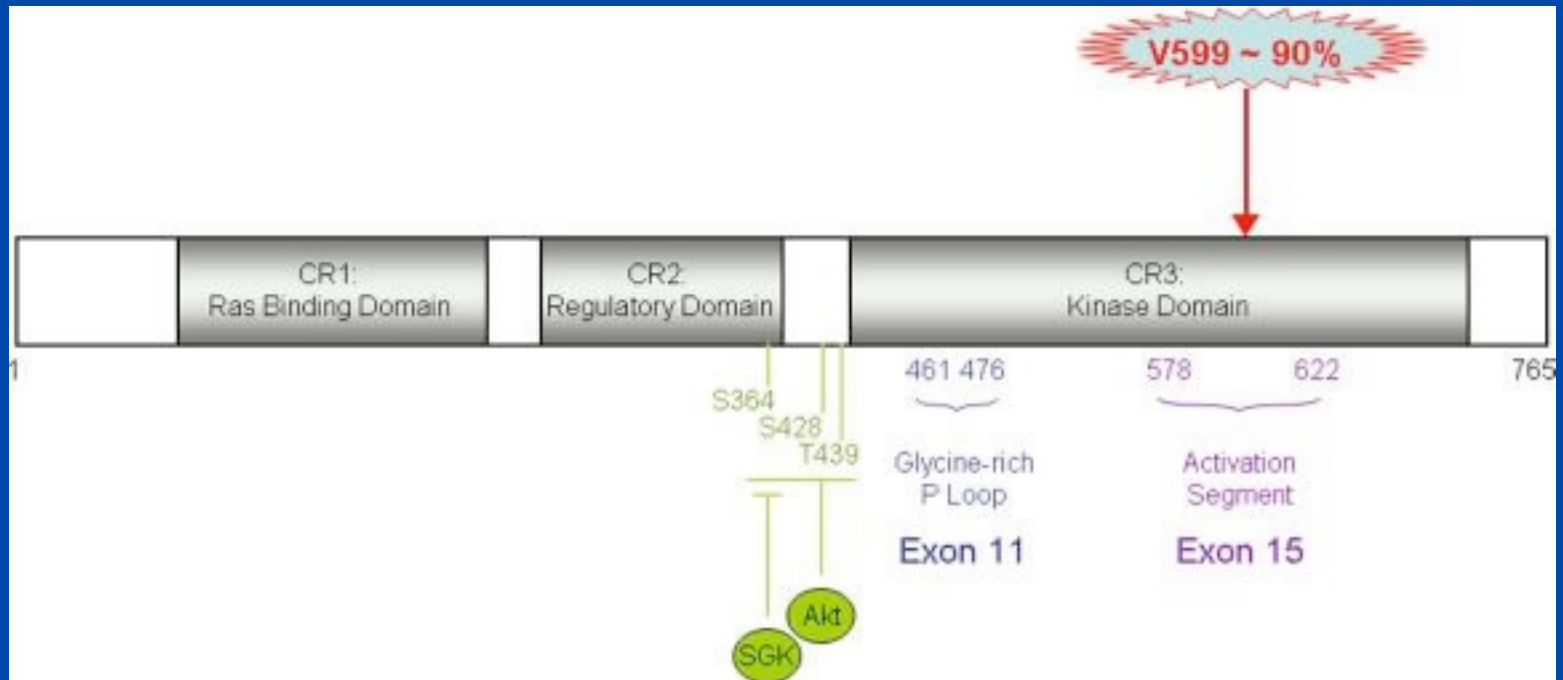
# Kamino Bodies



- Coalescent, pale pink bodies
- Multiple step sections may be necessary
- PAS and trichrome positive
- NOT apoptosis



# Genetic Alterations



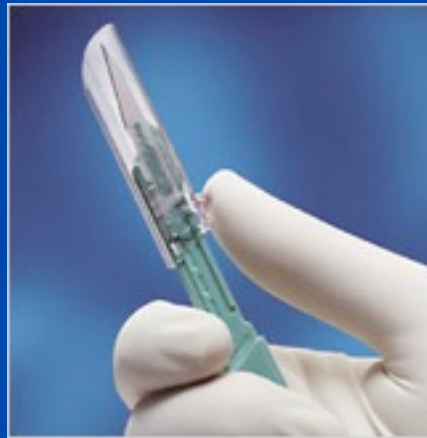Lesions n=95	B-RAF/N-RAS	H-RAS
Spitzoid MM	86% (31/36)  86% of mets (6/7)	0%
Spitzoid lesions susp. for MM	35% (8/23)	7% (1/15)
Atypical Spitz nevus	0% (0/22)	14% (3/22)
Spitz nevus	0% (0/14)	29% (4/14)

Am J Surg Pathol. 2005 Sep;29(9):1145-51 van Dijk MC, Bernsen MR, Ruiter DJ.



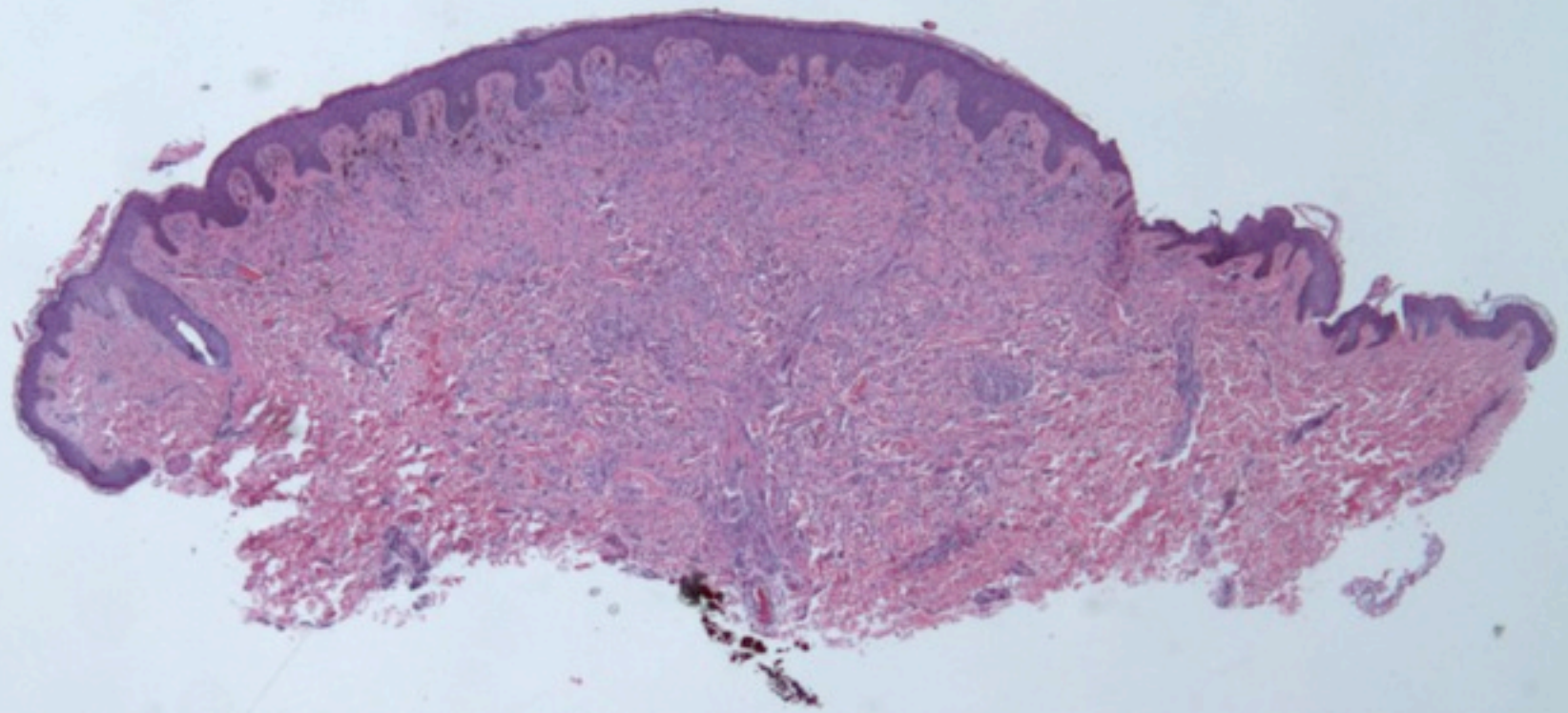
# Spitz nevi and spitzoid

# Should Spitz Nevi Be Excised?

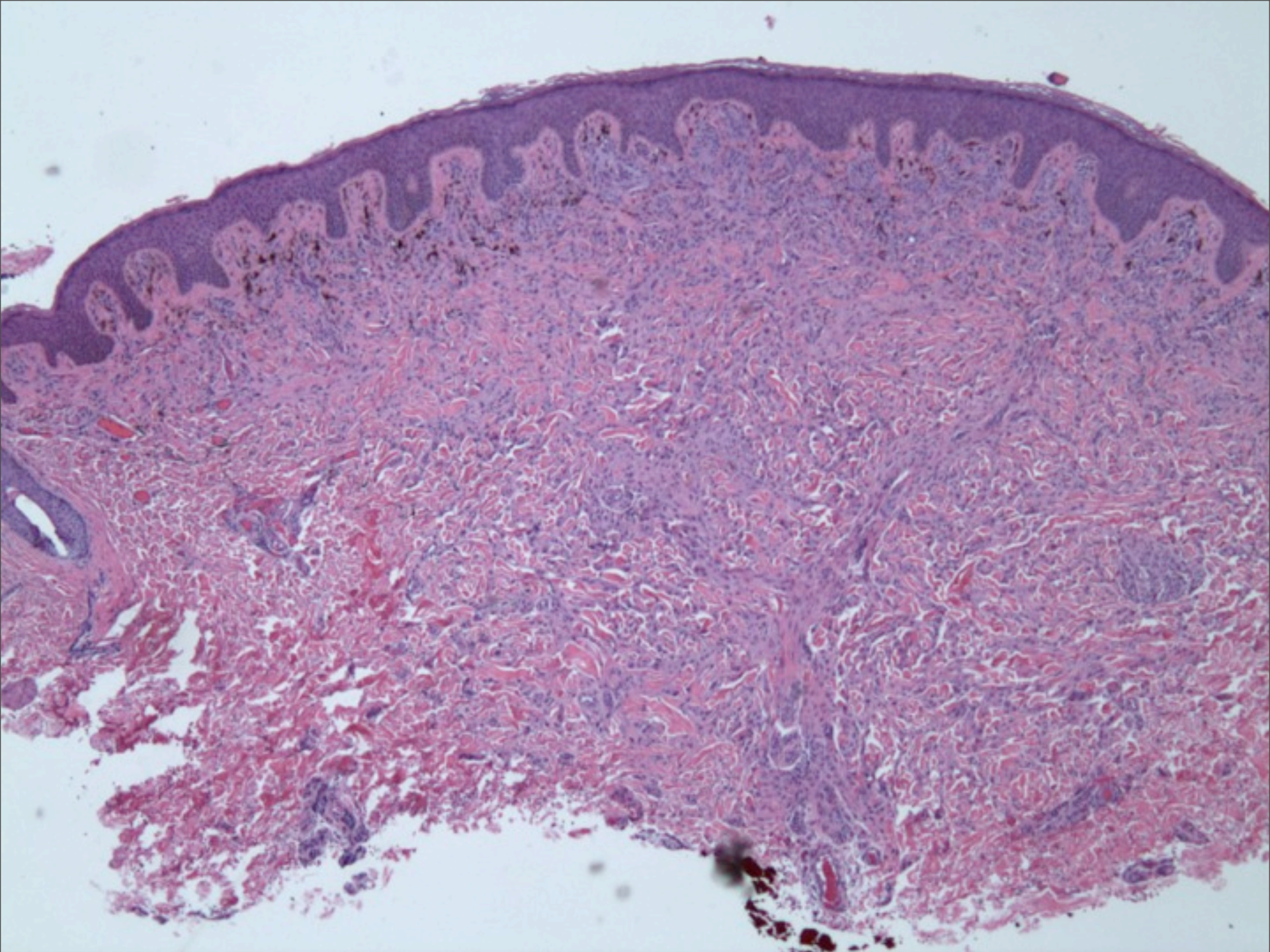




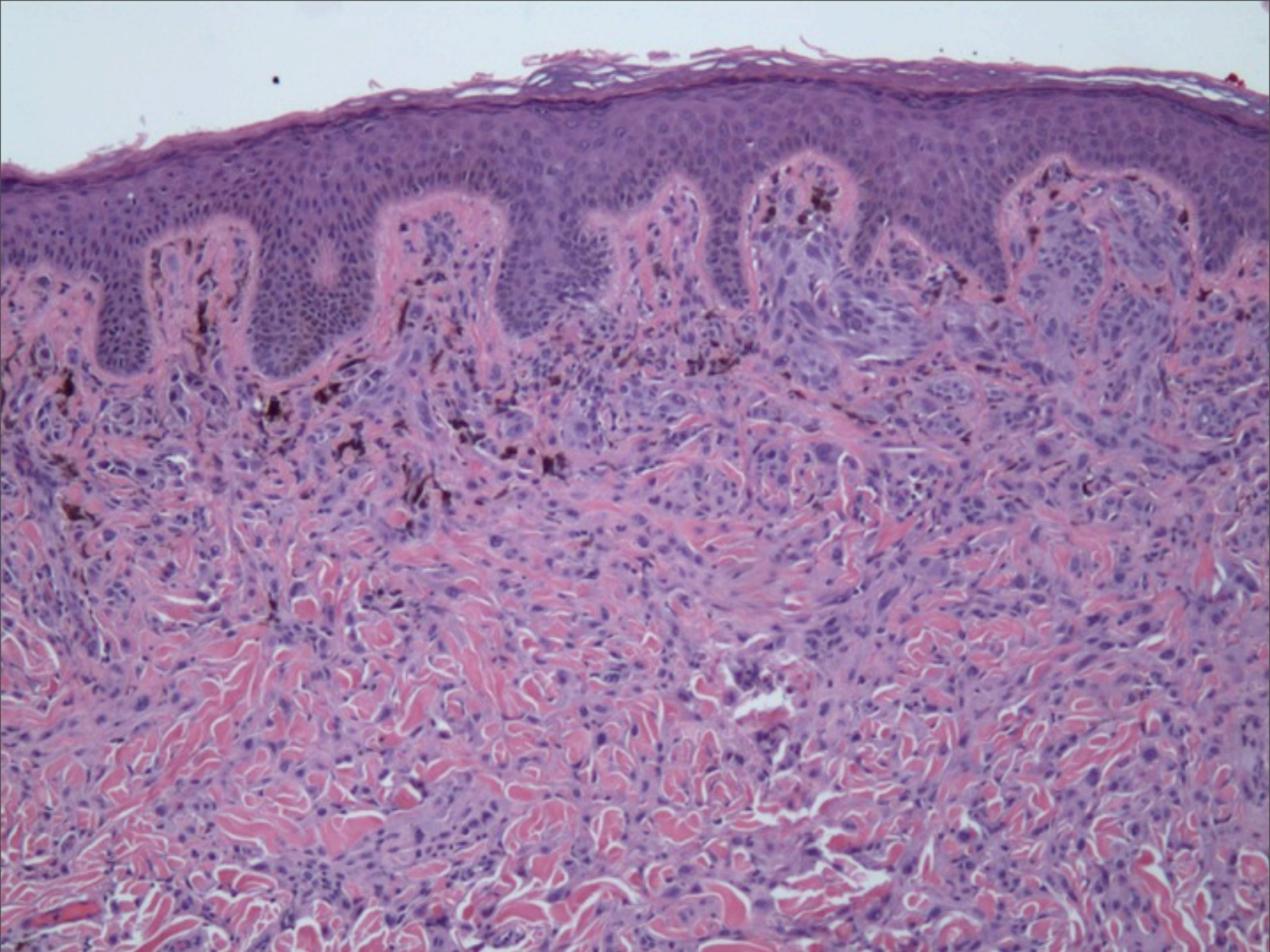
# Spitz Nevus or Not?



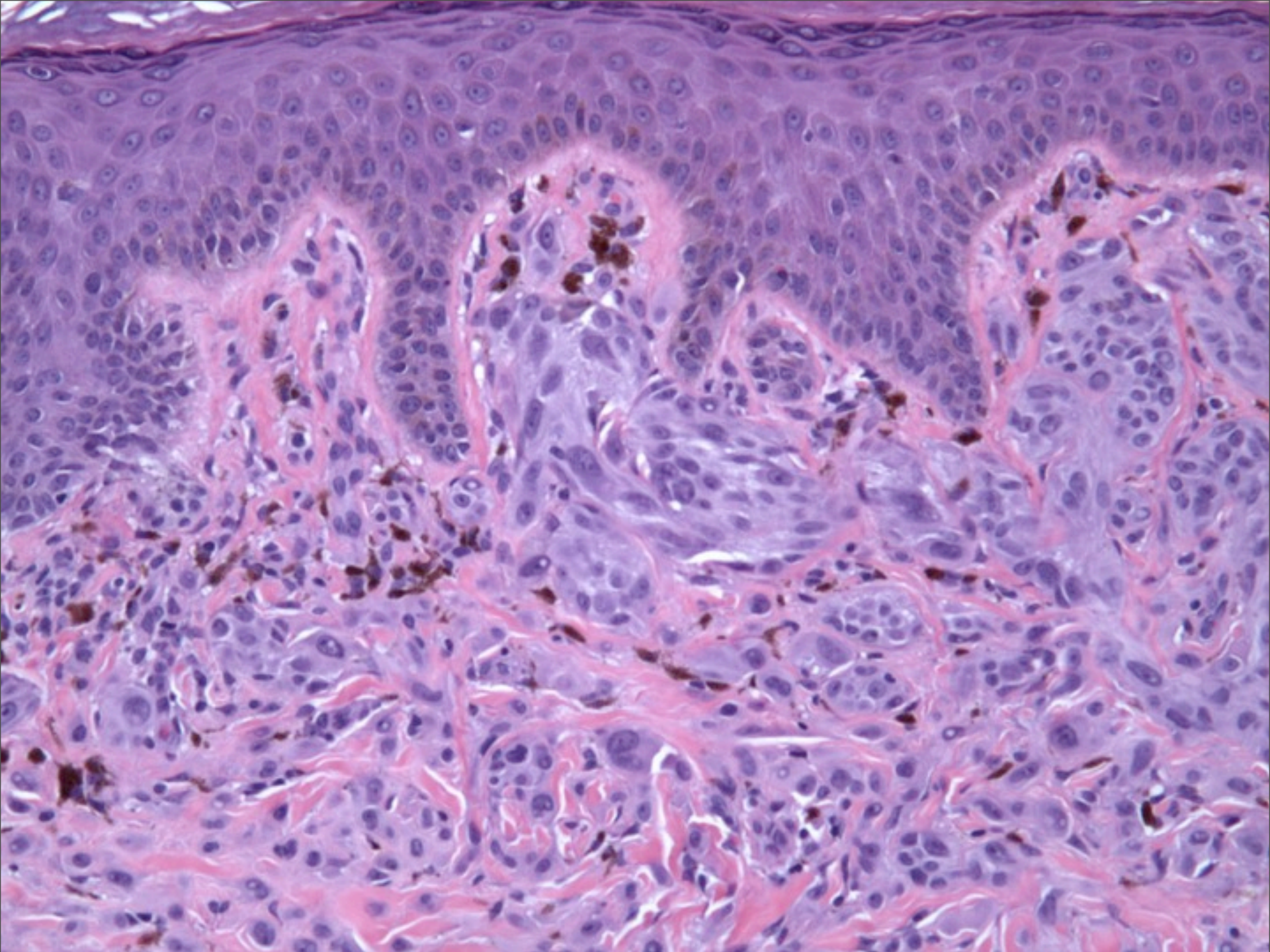




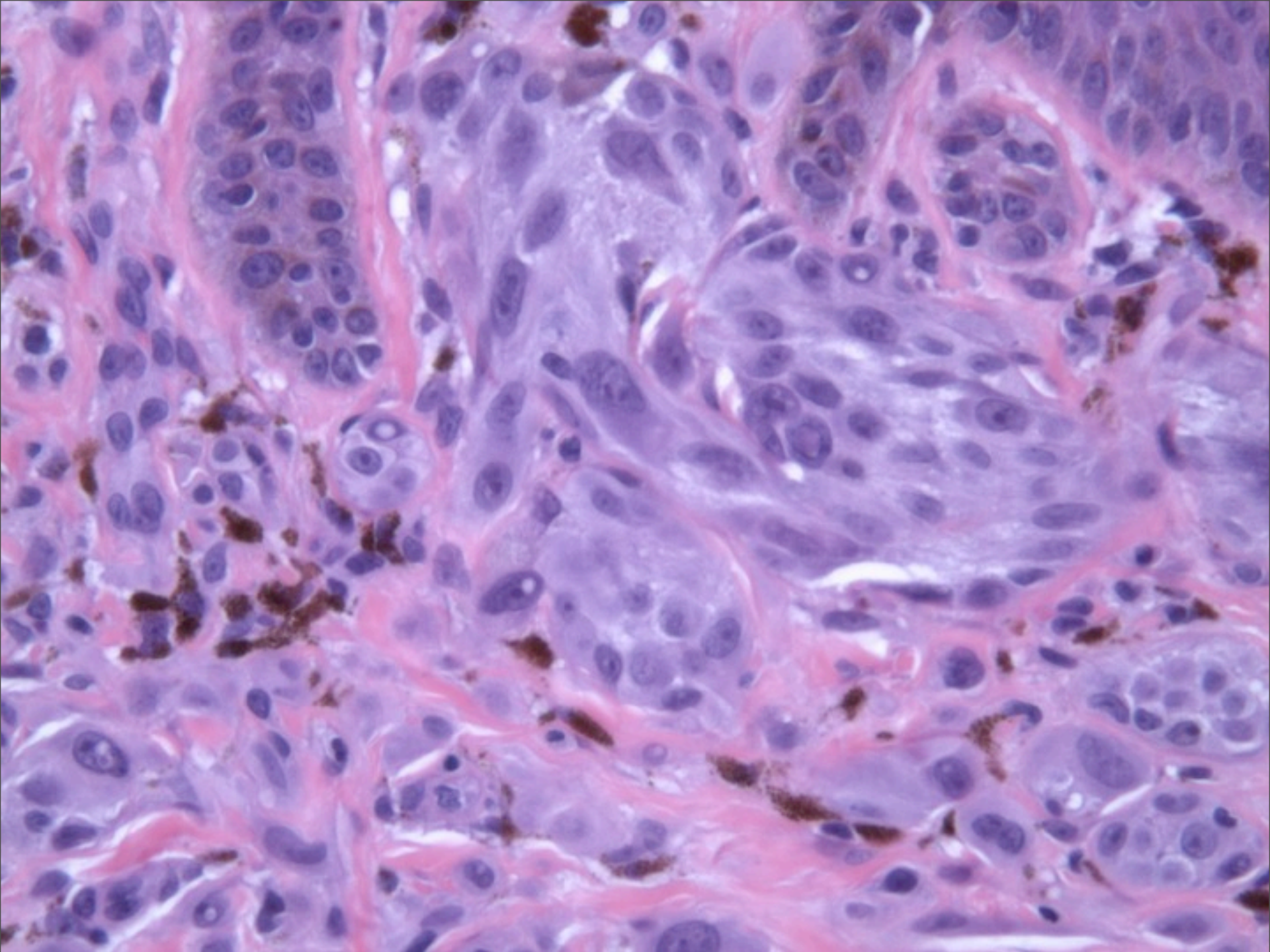




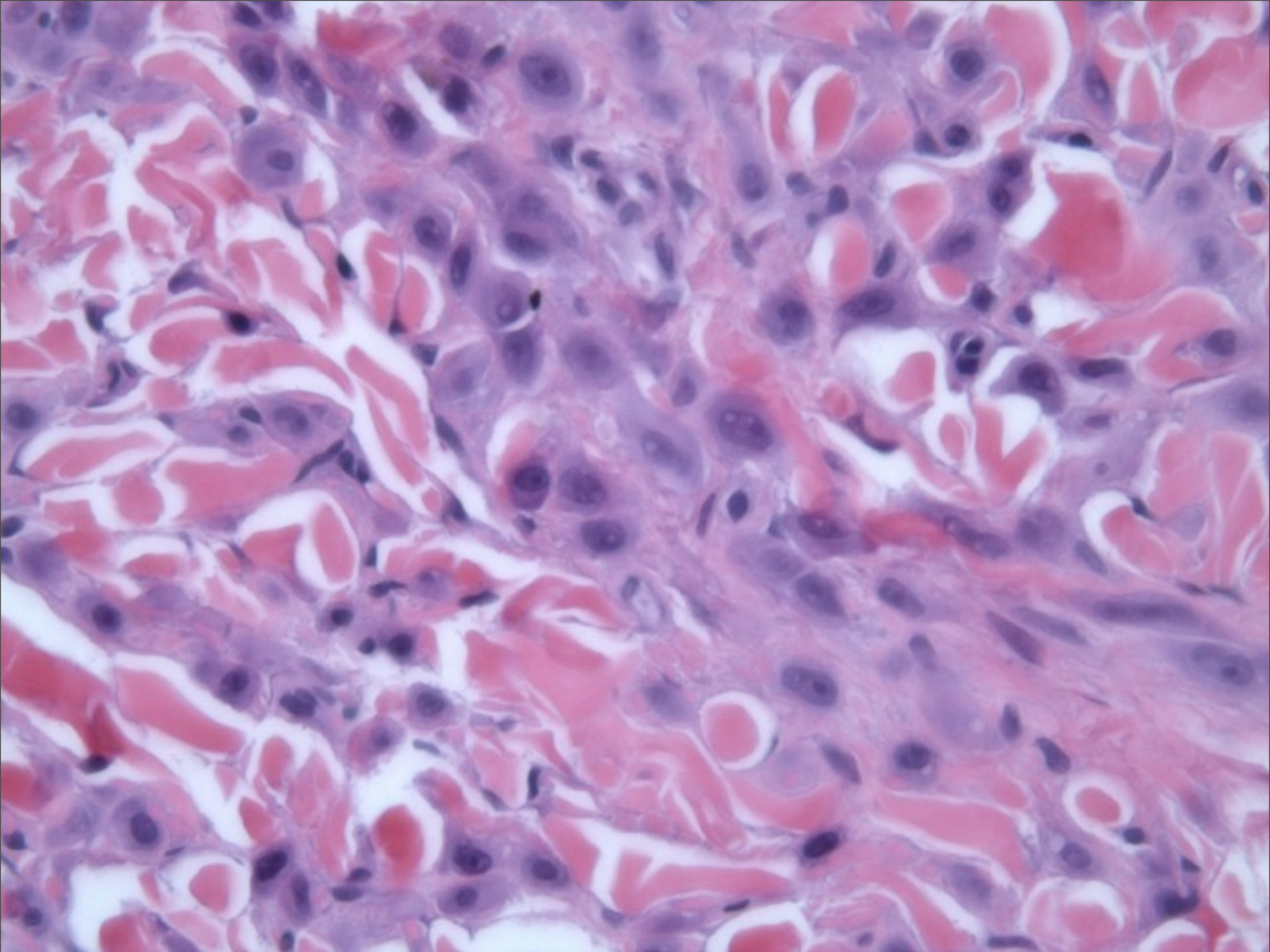




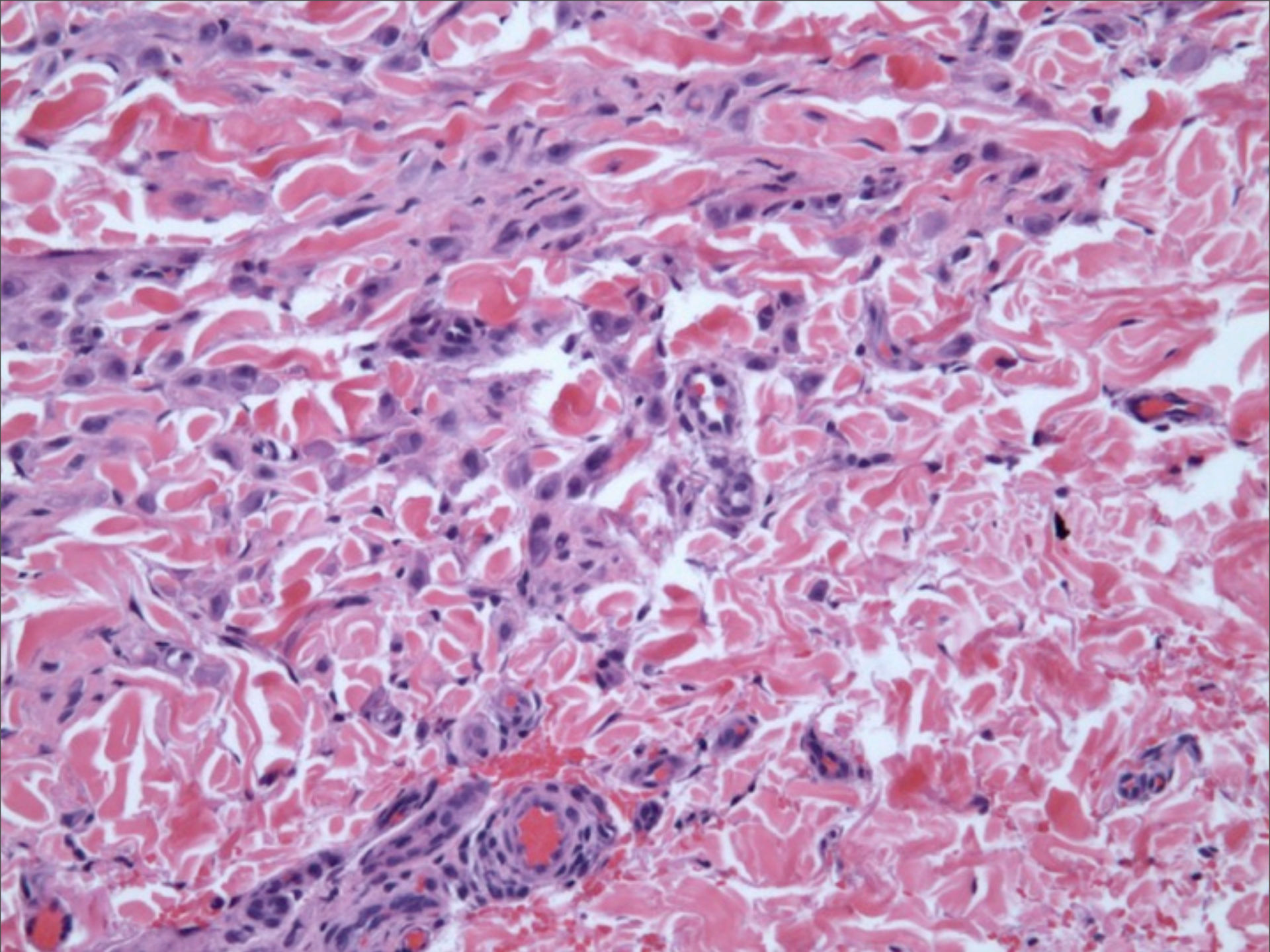




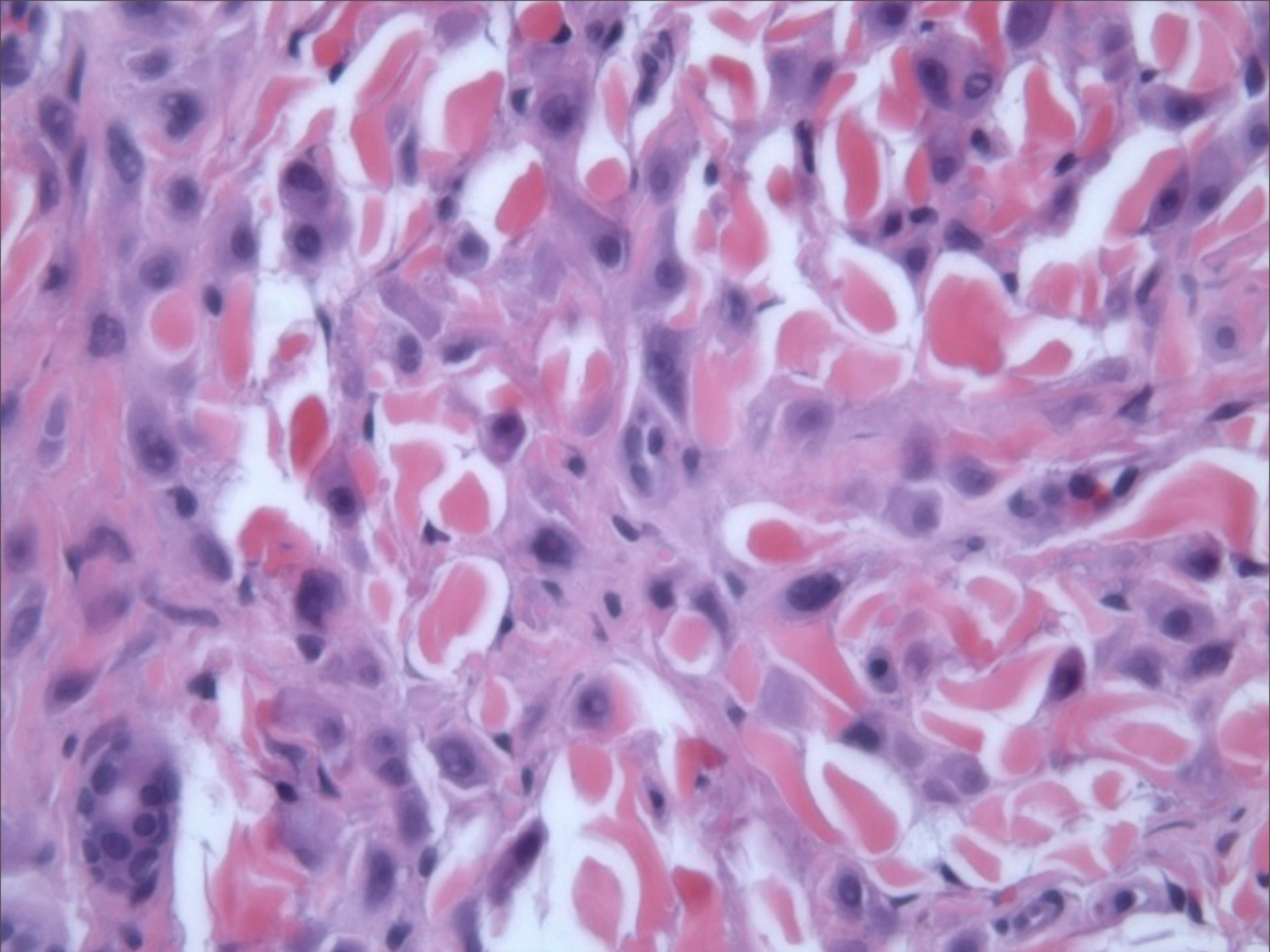






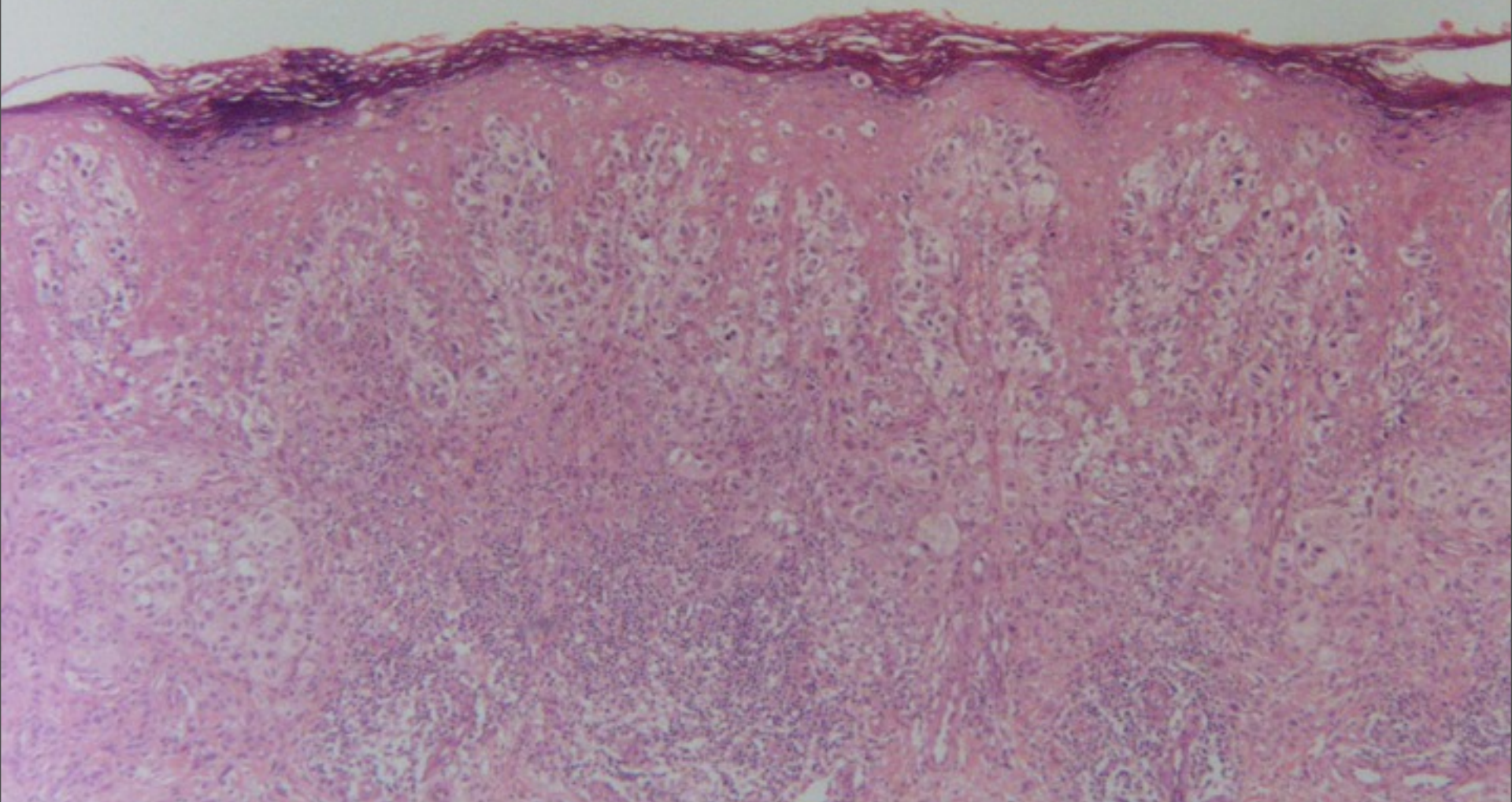




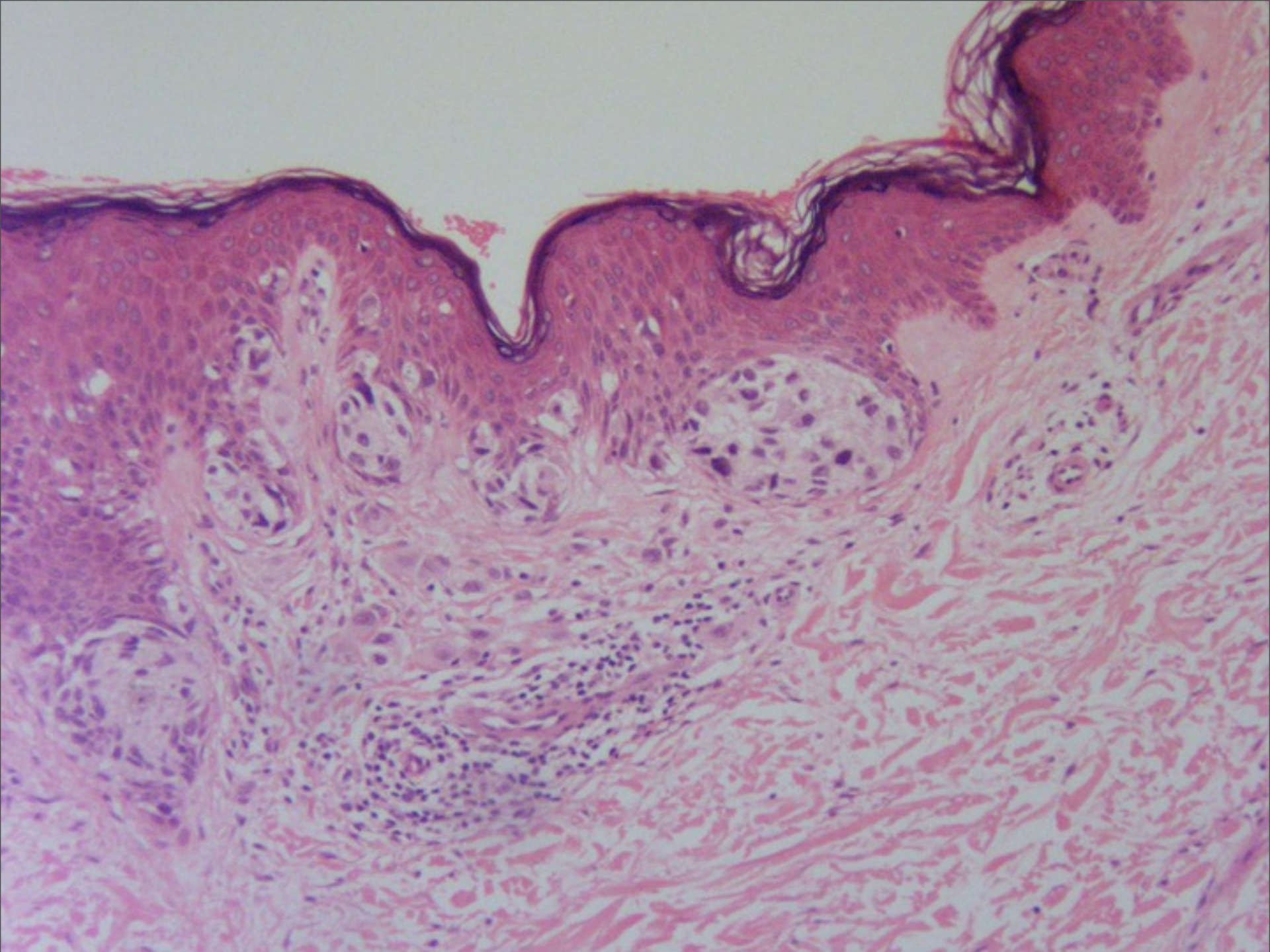


# Spitz Nevus with Sclerosing Features

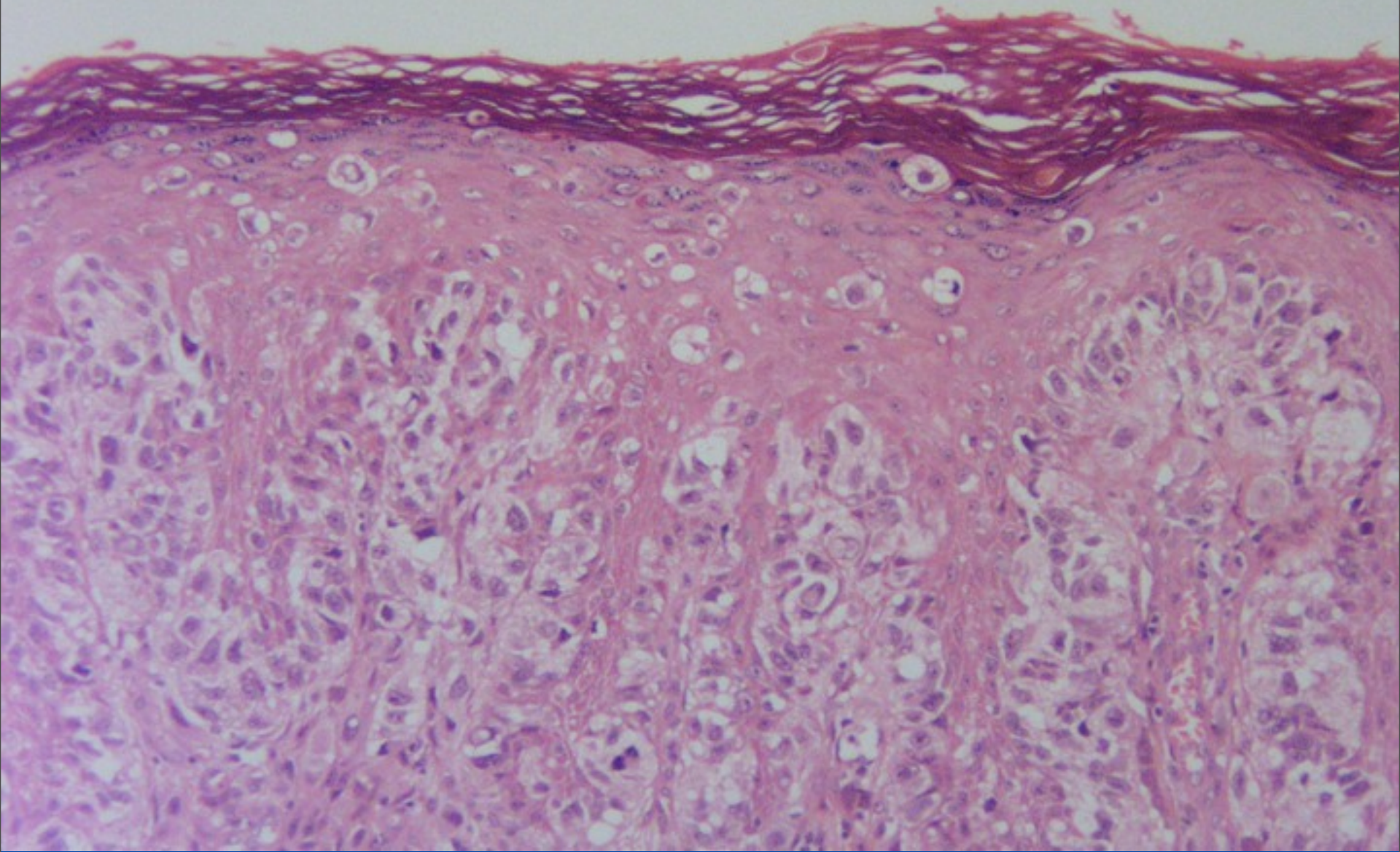




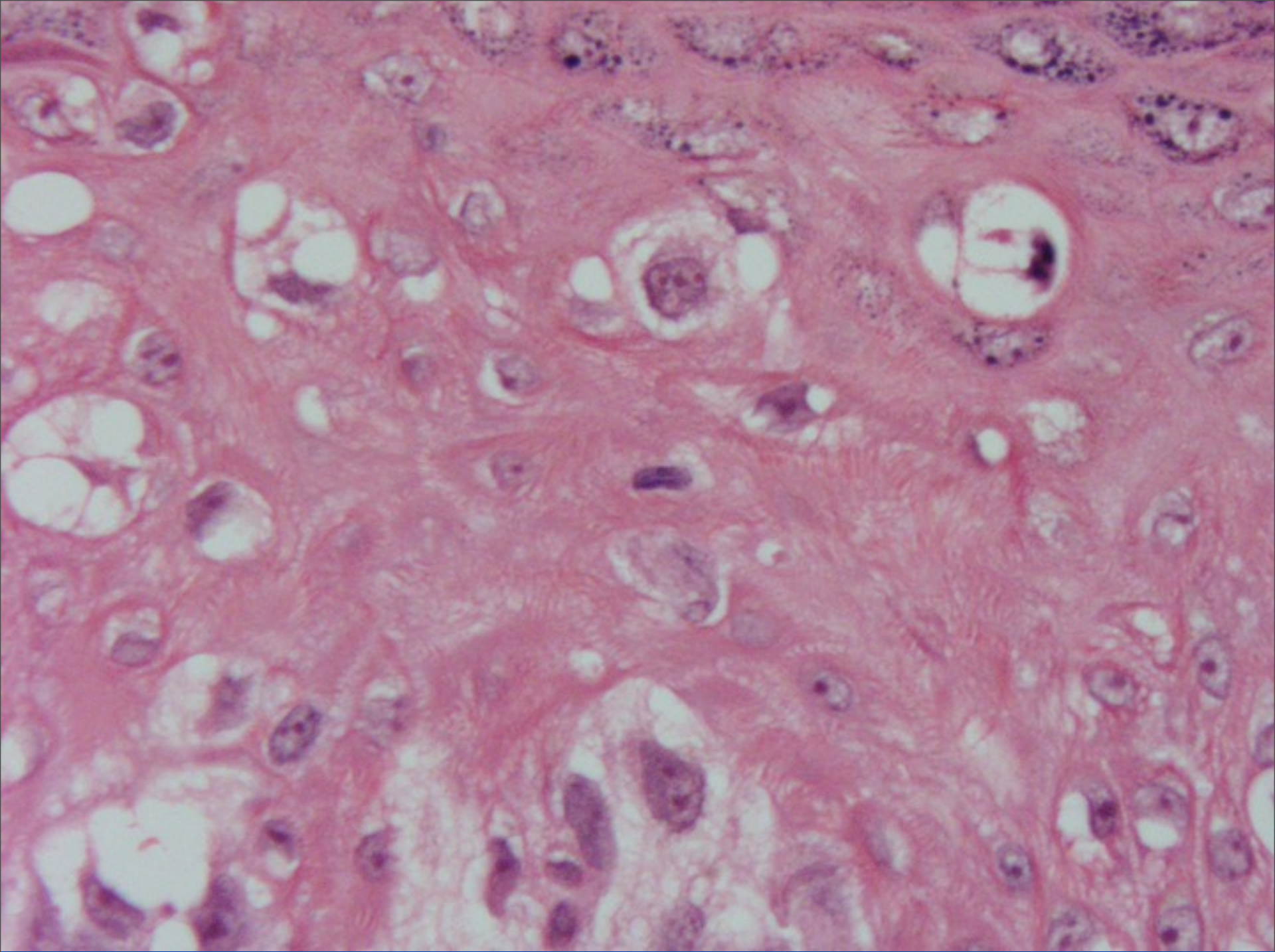




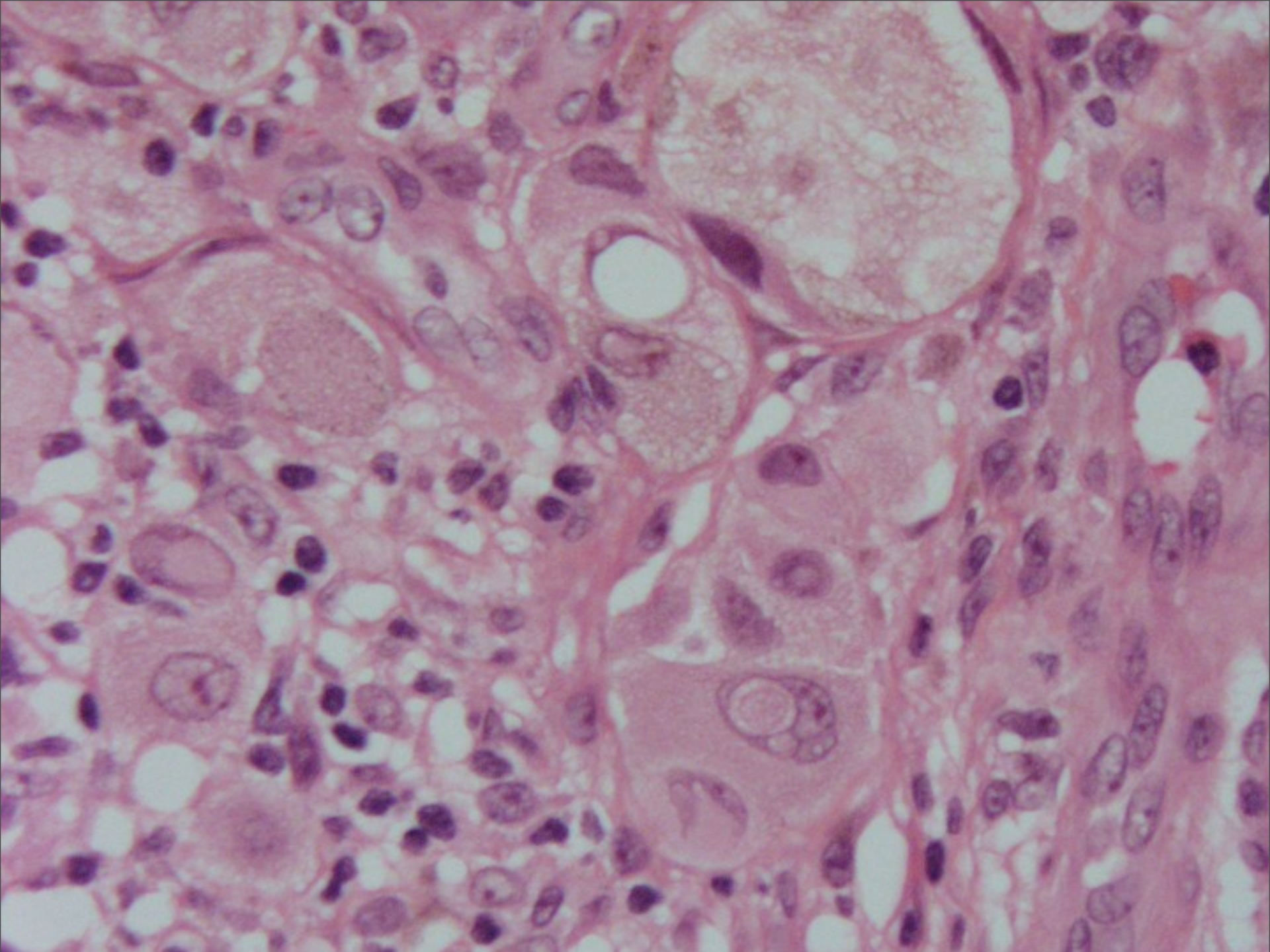












# Melanoma with Spitzoid Features



